

# Advanced concepts in orbital wall fractures

*Virtual surgical planning, intraoperative imaging,  
and clinical management*

Jesper Jansen





# Advanced concepts in orbital wall fractures

*Virtual surgical planning, intraoperative imaging,  
and clinical management*

**Jesper Jansen**  
Amsterdam, 2020

Financial support for printing and distribution of this thesis was kindly supported by:

NVMKA

KNMT

ACTA



Advanced concepts in orbital wall fractures

*Virtual surgical planning, intraoperative imaging, and clinical management*

Academic thesis, University of Amsterdam, The Netherlands

ISBN: 978-94-6332-652-0

Cover: C Photography by Celina Dorrestein

Layout: Ferdinand van Nispen, Citroenvlinder DTP&Vormgeving, [my-thesis.nl](http://my-thesis.nl)

Printing: GVO drukkers & vormgevers, Ede, The Netherlands

Copyright © 2020, J. Jansen, Amsterdam, The Netherlands

All rights reserved. No part of this publication may be reproduced or transmitted in any form, by any means, electronic or mechanical, including photocopy, recording or any information storage and retrieval system, without written permission of the author.

# Advanced concepts in orbital wall fractures

*Virtual surgical planning, intraoperative imaging,  
and clinical management*

ACADEMISCH PROEFSCHRIFT

ter verkrijging van de graad van doctor  
aan de Universiteit van Amsterdam  
op gezag van de Rector Magnificus  
prof. dr. ir. K.I.J. Maex

ten overstaan van een door het College voor Promoties ingestelde commissie,  
in het openbaar te verdedigen in de Aula der Universiteit  
op vrijdag 9 oktober 2020, te 11.00 uur

door  
Jesper Jansen  
geboren te Utrecht

## Promotiecommissie

<b>Promotores:</b>	prof. dr. A.G. Becking prof. dr. T.J.J. Maal	Universiteit van Amsterdam Radboud Universiteit Nijmegen
<b>Copromotores:</b>	dr. P.J.J. Gooris dr. L. Dubois	Universiteit van Amsterdam Universiteit van Amsterdam
<b>Overige leden:</b>	prof. dr. J. de Lange prof. dr. F.R. Rozema prof. dr. M.P. Mourits prof. dr. H.S. Tan dr. M.L.L. de Win dr. B. van Minnen	Universiteit van Amsterdam Universiteit van Amsterdam Universiteit van Amsterdam Vrije Universiteit Amsterdam Universiteit van Amsterdam Rijksuniversiteit Groningen

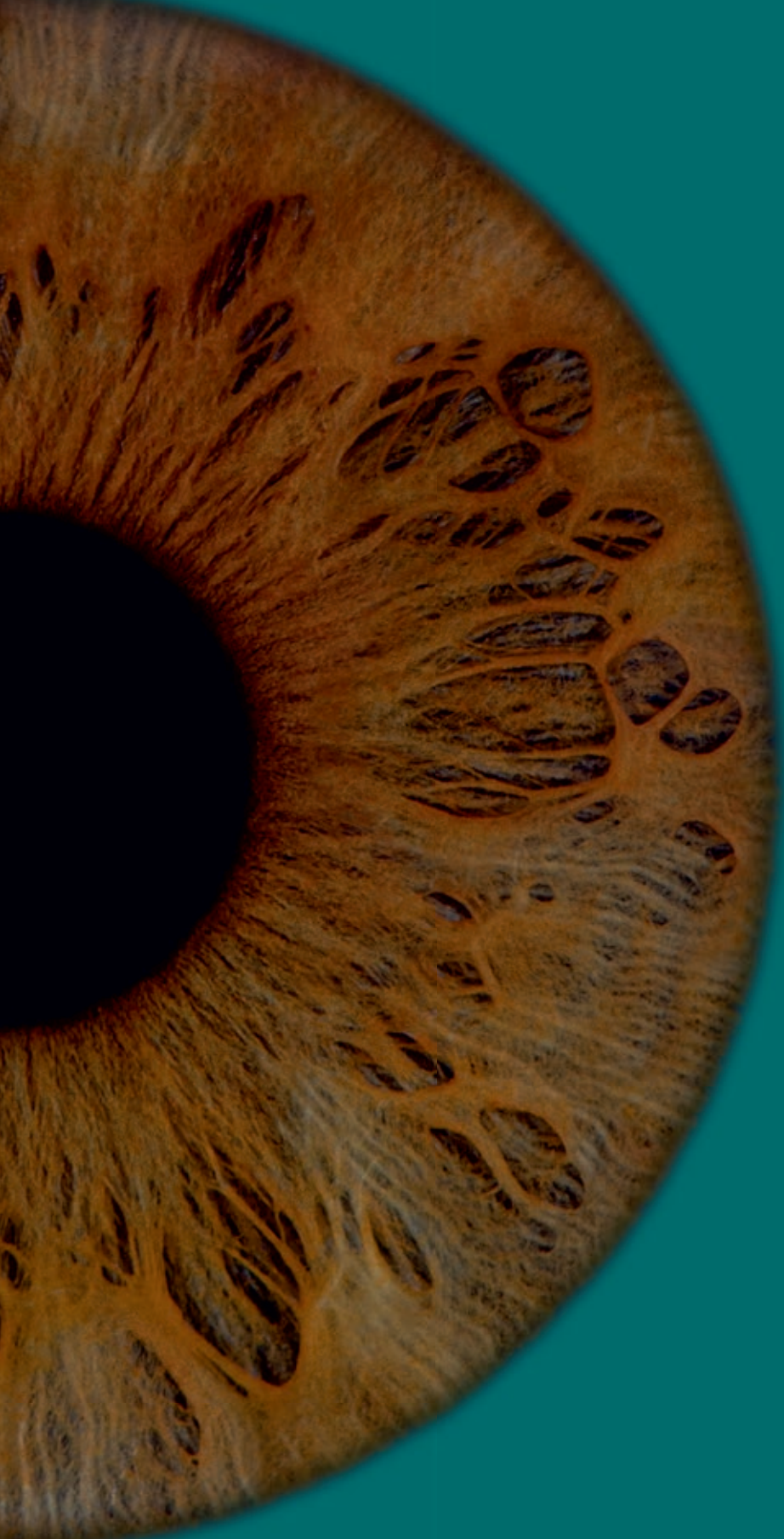

# Table of contents

	<b>Introduction</b>	
<b>Chapter 1</b>	General introduction and outline of this thesis	9
<b>Part I</b>	<b>Technological advancements</b>	
<b>Chapter 2</b>	Validation of a semi-automatic software segmentation method for orbital volume analysis <i>International Journal of Computer Assisted Radiology and Surgery, 2016</i>	27
<b>Chapter 3</b>	The use of virtual mirroring during preoperative planning of an orbital reconstruction <i>Journal of Oral and Maxillofacial Surgery, 2018</i>	47
<b>Chapter 4</b>	Computer-assisted preoperative planning to improve implant position in orbital reconstruction <i>Journal of Cranio-Maxillofacial Surgery, 2018</i>	65
<b>Chapter 5</b>	Improved implant position using intraoperative imaging in orbital reconstruction <i>British Journal of Oral and Maxillofacial Surgery, 2020</i>	83
<b>Part II</b>	<b>Clinical perspective</b>	
<b>Chapter 6</b>	A nonsurgical approach with repeated orthoptic evaluation is justified for most blowout fractures <i>Journal of Cranio-Maxillofacial Surgery, 2020</i>	99



	<b>Discussion and summary</b>	
<b>Chapter 7</b>	General discussion and future perspectives	125
<b>Chapter 8</b>	Summary in English and Dutch	139
	<b>Appendices</b>	
	Contributing authors	156
	List of publications	161
	PhD portfolio	164
	Acknowledgements / Dankwoord	166
	About the author	174



CHAPTER  
1

**General introduction  
and outline of this thesis**



## General introduction

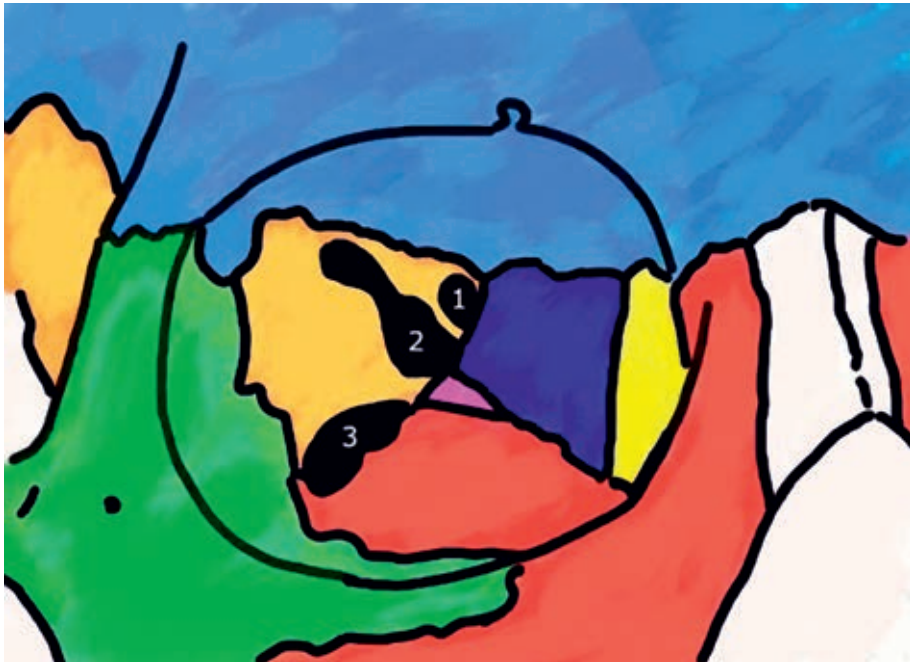To take the next step in the management and treatment of orbital wall fractures, also called blow-out or orbital floor and medial wall fractures, it is helpful to be aware of the scientific developments of the past. In 1982, doctor K. de Man was the first Dutch oral and maxillofacial (OMF) surgeon to write a PhD thesis on orbital wall fractures<sup>1</sup>. Some of his most important findings were: that an important indication for orbital reconstruction is a significant limitation in vertical eye movement combined with a positive forced duction test or significant herniation of orbital tissue into the maxillary sinus. If the periorbita is intact, there is no indication for orbital reconstruction. He concluded that there is a need for individualised treatment in orbital wall fractures, as there is no single method of treatment that can be considered ideal. In the same period, ophthalmologist professor L. Koornneef did revolutionary anatomical and histological research on the musculofibrous network of the orbit<sup>2</sup>. He advocated a conservative approach in the management of orbital wall fractures, while others favoured early surgical intervention<sup>3</sup>.

Research at the orbital unit of the Department of OMF surgery at the Amsterdam UMC location AMC started in 2012 and focused on advanced technological concepts of orbital reconstruction and the management of orbital wall fractures. Since the beginning, medical engineers were part of the research team. Efforts resulted in a series of systematic reviews on the current controversies in orbital reconstruction<sup>4-6</sup>. Another line of research was centred around navigation-assisted orbital reconstruction and advanced solutions, such as a patient-specific implant (PSI)<sup>7,8</sup>. The first milestone was the PhD thesis of doctor L. Dubois in 2016. This PhD thesis is a continuation of the research performed at the OMF surgery orbital unit, partly in collaboration with the Department of Ophthalmology.

### **Orbital anatomy and trauma mechanism**

Comprehensive knowledge of the anatomy and the trauma mechanism is essential to understand the challenges in the treatment of orbital floor and medial wall fractures. The bony components of the orbit originate from seven surrounding bones: frontal, lacrimal, ethmoid, zygomatic,

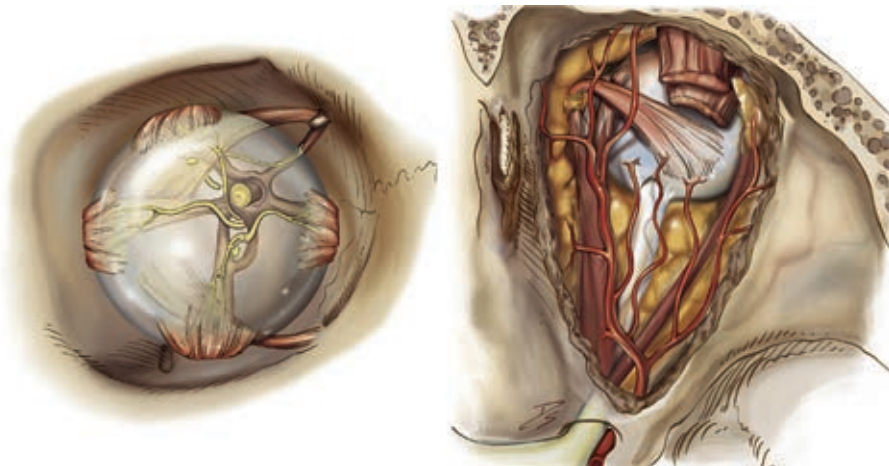
maxillary, palatine, and sphenoid (Fig. 1). These bones form a conical shape, with the apex proximally, to support and protect the soft tissue. Both the apex and the anterior orbital rim consist of thick cortical bone. The orbital floor and medial wall, in particular, are thin and prone to fracture during trauma. The orbit is surrounded by the intracranial space, nasal cavity, lacrimal duct, frontal sinus, and maxillary sinus<sup>9-11</sup>.



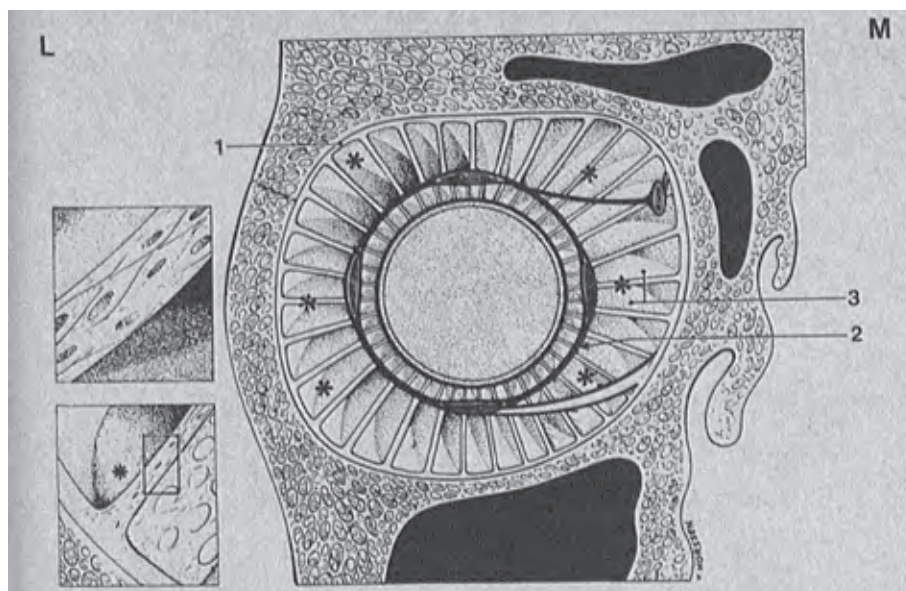
**Figure 1** The bones and major apertures that compose the orbital cavity. Frontal (*light blue*), lacrimal (*yellow*), ethmoid (*purple*), zygomatic (*green*), maxillary (*red*), palatine (*pink*), and sphenoid bone (*orange*). Optic foramen (1) and superior (2) and inferior (3) fissure.

Three apertures, the optic foramen and the inferior and superior orbital fissures, give access to the orbital cavity for several critical neurovascular structures, which are bounded by thick sphenoid bone (Fig. 1). The optic nerve and ophthalmic artery pass through the optic foramen. The zygomatic nerve and infraorbital nerve, vein, and artery enter through the inferior orbital fissure. The superior orbital fissure contains the oculomotor, trochlear, abducens, and ophthalmic nerve. The ophthalmic veins pass through both fissures<sup>10</sup>.

Together with these neurovascular structures, the soft tissue in the orbital cavity is composed of adipose tissue, connective tissue, muscles, and the globe (Fig. 2). The majority of soft tissue is fat and can be subdivided into extraconal and intraconal fat. It provides support, protection, and assists in the movement of the globe and muscles. Eye movement, with rotation over three axes, is a well-timed collaboration of the inferior, superior, medial, and lateral rectus muscles and the superior and inferior oblique muscles. The connective tissue is a complex framework (Fig. 3). The globe and extraocular muscles are enclosed by fascia sheaths. Several septa and ligaments, containing smooth muscle cells, are aligned between the periorbit and these sheaths. They compartmentalize the orbit and are a suspension system which seems to be crucial to the normal functioning of the globe<sup>2</sup>. Lockwood's ligament is an example of a transverse suspensory ligament for the globe. It vertically stabilizes the globe and provides the framework for the inferior rectus and oblique muscles. The lacrimal system and the eyelids, supported by the medial and lateral canthi and the superior and inferior tarsal plates, are also important structures to protect the globe and to take into account during the surgical approach and the orbital reconstruction, as iatrogenic damage can cause serious complications.



**Figure 2** The coronal (left) and axial (right) view of the orbital cavity showing adipose tissue (orange), muscles (red striped), nerves (yellow and white tubular structures), arteries (red tubular structures), the globe (transparent and white), and bony orbit and skull (beige). Reprinted from reference 12 © (2019), Atlas of Endoscopic Sinus and Skull Base Surgery, with permission from Elsevier<sup>12</sup>.



**Figure 3** A schematic reproduction of the suspension system with the periorbit (1), the common muscle sheath at globe level (2), and the fibrous septa (3). Reprinted from reference 2 © (1977), *Archives of Ophthalmology / JAMA Ophthalmology*, with permission from American Medical Association<sup>2</sup>.

The trauma mechanism of an orbital wall fracture can be explained by the hydraulic and buckling theory<sup>13,14</sup>. In the hydraulic theory, force is directed to the globe and intraorbital soft tissue. The intraorbital pressure is elevated due to retropulsion and directed towards the orbital walls. This trauma mechanism accounts for large fractures of both the orbital floor and medial wall with potential herniation of soft tissue<sup>15</sup>. The buckling theory states that direct force is applied to the orbital rim and transferred to the orbital floor, usually causing a small anterior orbital floor fracture without herniation of soft tissue. Both mechanisms combined probably contribute to the formation and the pattern of the fracture<sup>14</sup>. The trauma not only results in a fracture, but also causes soft tissue damage. Both adipose and muscle tissue herniate into the fracture. The suspension system and periorbita will be affected to some extent. The actual damage is initially difficult to assess due to swelling, contusion of muscles, and the presence of haematoma. The goal of surgical intervention is an anatomical reconstruction of the bony walls and the release of incarcerated soft tissue to restore orbital function. The regenerative capacity of the soft tissue and the amount of damage caused by the surgery itself is unpredictable.



## Surgical principles

The shape of the bony orbit and the intricate architecture of the soft tissue pose surgical challenges. Orbital reconstruction is performed in a confined space with a limited overview close to vital and delicate structures. This presents a risk of iatrogenic damage and surgical complications. Detailed planning and adequate exposure of the orbital floor and medial wall is necessary to avoid this as much as possible.

Widely used approaches to restore the orbital boundaries after an orbital wall fracture are transconjunctival, subtarsal, and subciliary<sup>16,17</sup>. The ideal approach is safe, easy, and quick to perform, facilitates a perfect exposure of the fracture, and has minimal risk of complications. The subtarsal and subciliary approach are both transcutaneous approaches. The subtarsal approach is allegedly the easiest approach, it creates direct exposure to the orbital floor and the scar can be concealed in a skin crease. There is a moderate risk of complications such as lid shortening and ectropion. The subciliary approach is more demanding and allows the best exposure of the orbital rim and floor. The disadvantage is a higher incidence of complications, such as scar formation, lid oedema, ectropion, and scleral show. The transconjunctival approach has no visible scarring as it hides behind the lower eyelid. The initial exposure could be moderately inferior to the other approaches, but the risk of complications, such as entropion, is low. A major advantage of this approach is that the medial wall can be exposed with a transcaruncular extension and exposure of the floor can be improved with a lateral canthotomy<sup>16,17</sup>. A good overview is required to see the fracture and the landmarks.

Surgical guidance with the use of anatomical landmarks is important for the orientation of the surgeon during orbital reconstruction. The orientation is improved by identifying and measuring the distance between each landmark in relation to the fracture<sup>18</sup>. The surface area of a fracture is usually overestimated by the surgeon and computed tomography (CT) measurements are the most consistent and accurate<sup>19</sup>. An excellent overview is particularly important in complex fractures with altered anatomy and protruding adipose tissue. The most anterior landmark that can be identified during the approach is the inferior

orbital rim and this is often used to fixate an implant for orbital wall reconstruction. The orbital process of the palatine bone is in fact the posterior ledge and usually remains intact after an orbital wall fracture, due to its position and thickness<sup>20</sup>. Together with the inferior orbital rim this is an important landmark, as it indicates the desired dorsal position of an implant and facilitates posterior support. It is located anterior to the superior orbital fissure, so the surgeon should be careful when approaching this area<sup>20</sup>. When visualisation of the posterior ledge is difficult, an alternative landmark is the posterior wall of the maxillary sinus<sup>21</sup>. The infraorbital nerve can also serve as a guide for the surgeon in both the depth and direction of the dissection along the orbital floor<sup>22</sup>. This structure is often involved in trauma and as such cannot be used as reliable guidance in most cases. The inferomedial strut can be additionally used as a landmark to identify the transition from the orbital floor to the medial wall. Several ligaments are attached to the inferomedial strut for globe support. This strut is often affected in complex fractures<sup>23</sup>. Apart from the identification of anatomical landmarks, the success of orbital reconstruction is influenced by the implant material.

A wide variety of implant materials are used to reconstruct an orbital wall fracture. The goal of orbital reconstruction is to restore the pretraumatised orbital anatomy and function, predominantly for the correction of enophthalmos and diplopia. Implant materials must have certain characteristics to achieve this. The ideal material has good stability and fixation, has an ideal architecture or contouring abilities to restore volume and shape, is biocompatible, facilitates drainage of fluids, has no donor site morbidity, is radiopaque, and is readily available at an acceptable price<sup>6</sup>. Titanium implants adhere to most of these demands and are widely used, either as preformed custom plates, patient-specific implants, or titanium meshes for intraoperative bending. Autologous bone grafts used to be the gold standard based on biocompatibility. The disadvantages are donor site morbidity, unpredictable resorption rate, and difficulty to shape the graft. An alloplastic material like titanium is now considered the gold standard, yet still a lot of research is performed to find the best suitable biomaterial for orbital reconstruction.

## Technological developments

The principles and limitations of orbital reconstruction have triggered technological developments in the past two decades. Even with a perfect approach, a good overview of the anatomical landmarks, and the ideal implant material, there is still a need for technological aids. Several studies have demonstrated that computer-assisted surgery (CAS), based on a CT scan, does assist the surgeon in achieving a better and more predictable treatment outcome<sup>24,25</sup>. CAS consists of several preoperative, intraoperative, and postoperative components. Virtual three-dimensional (3D) diagnostics and preoperative planning software ensures a better inspection of the problem and the possible solutions. The software transforms the CT scan into a 3D reconstruction of the skull. When a patient with an orbital wall fracture is presented, it is possible to measure the volume of both orbital cavities and segment the unaffected side. The unaffected side can then be mirrored and used as a template for the affected side. Virtual surgery is possible by importing STL data of different implants to check for the correct size. When this virtual preoperative plan is compared with a postoperative CT scan of the patient, the accuracy of the treatment can be evaluated<sup>26</sup>. This is an important learning tool for an inexperienced surgeon. Navigation-guided reconstruction allows for intraoperative guidance and control, to make the orbital reconstruction more accurate and predictable<sup>27</sup>. Besides intraoperative navigation, intraoperative imaging can be used to evaluate the position of the orbital implant during surgery. A drawback of intraoperative imaging is that it is cumbersome, time-consuming, and exposes the patient to extra ionizing radiation.

## Management of orbital wall fractures

The management of orbital wall fractures is at the interface between different specialties, including OMF surgery, ophthalmology, and to a lesser extent plastic surgery and ear, nose, and throat surgery. Over the years, distinct cyclicity in the various treatment strategies can be observed, in which nonsurgical and surgical treatment alternately predominate<sup>28</sup>. The new technological developments in CAS provide a wide variety of additional supportive treatment options. The ultimate goal of every technological development is enhancing surgical outcome.

This may make surgeons more inclined to operate, instead of ensuing a nonsurgical approach. A nonsurgical approach for most orbital wall fractures has been propagated in the past, based on the regenerative capacity of the body<sup>3</sup>.

The indications and timing of surgery are the main topics in the ongoing debate on the management of orbital wall fractures. Generally, small asymptomatic fractures do not need surgery and larger fractures with early enophthalmos do acquire an orbital reconstruction. The indications for immediate surgery are also obvious: vision-threatening trauma, retrobulbar haematoma, significant globe displacement, and a trapdoor phenomenon with muscle entrapment ('white-eye' orbital wall fracture and restrictive strabismus). Permanent damage to the orbital soft tissue will probably occur without intervention in these cases. The main controversy arises when confronted with large orbital wall fractures without early enophthalmos. In daily clinical practice, surgery is indicated based solely on the size ( $>2 \text{ cm}^2$  or  $>50 \%$ ) of the fracture measured on a CT scan or in case of severe diplopia and limited motility within several days after trauma<sup>29,30</sup>. The size of the fracture does not necessarily correlate to late enophthalmos and severe diplopia could still resolve without intervention. There is no consensus concerning the ideal timing of an orbital reconstruction. The assumption is that early surgery ( $<2$  weeks) has a better outcome and causes less iatrogenic damage<sup>31</sup>. As a consequence, there might be overtreatment of patients with early surgery that might have recovered spontaneously over time. There is also evidence of a good outcome after late orbital reconstruction<sup>32</sup>. The management of orbital wall fractures and clinical protocols should be regularly updated based on the latest scientific evidence.

## Aims and outline of this thesis

The aim of this thesis is twofold. Firstly, the aim is to investigate the added value of several individual components in the workflow of computer-assisted orbital reconstruction. The hypothesis is that more detailed information provides better and more predictable outcome. The main focus is on diagnostics, preoperative planning, and intraoperative control. Secondly, the aim is to upgrade the clinical management of these fractures by evaluating the available literature and convert this into a new clinical protocol with special emphasis on functional outcome.

### Introduction

In **chapter 1** (this chapter), the general introduction and outline are presented.

### Part I Technological advancements

Virtual planning software creates a better overview, more accurate measurements of the fracture site, and grants a valuable insight into the surgical dilemmas. Computer-assisted diagnostics, surgical planning, intraoperative navigation, and intraoperative imaging are ideally all incorporated in the workflow of orbital reconstruction.

Orbital wall fractures are often unilateral. Assessing the difference in volume between the affected and unaffected sides can be indicative for the severity of the fracture. Manual measurement is time-consuming and not applicable in clinical practice. Therefore, a (semi-)automatic method is a practical solution. In **chapter 2**, three (semi-)automatic methods to measure the orbital volume of the intact bony orbit are evaluated. One of the issues is that the orbital cavity has several apertures and to ensure an enclosed space, the orbital boundaries need to be defined with virtual planes. In this study, the aim is to test the speed, accuracy, and reproducibility of these methods.

If there is an indication for orbital reconstruction, the computer-assisted surgery workflow begins with segmentation and mirroring of the unaffected side onto the contralateral affected side. Virtual preoperative

planning is necessary to quantify the volume increase and to plan the position of the implant. It produces an easy to understand three-dimensional (3D) virtual template. This mirroring technique is used on the assumption that both orbital cavities are symmetrical. In **chapter 3**, the best semi-automatic method for volume measurement is used to investigate whether the volume and contour of both orbital cavities are similar when mirrored. Considerable differences in volume or contour between both cavities may lead to fundamental errors in planning the orbital reconstruction. In this study, the aim is to measure the degree of asymmetry between both orbital cavities.

The studies presented in **chapters 4 and 5** are part of a series of cadaveric research on computer-assisted technology and focus on intraoperative control during an orbital reconstruction. Both studies are performed using cadaveric heads with intentionally created, bilateral, complex orbital wall fractures. The primary outcome is the degree of improvement of the implant position. In **chapter 4**, 3D diagnostics and preoperative virtual planning are used to prepare the surgeon for the orbital reconstruction. The surgeon is able to examine both the CT scan and the preoperative virtual plan on a computer screen in the operating theatre to improve the position of the implant. The aim of this study is to evaluate the accuracy and predictability of 3D diagnostics and preoperative virtual planning in orbital reconstruction, without the use of intraoperative navigation. In **chapter 5**, the effects of intraoperative CT imaging in orbital reconstruction are discussed. The question is whether an improved surgical outcome outweighs the disadvantages such as radiation exposure, increased operation time, and costs. The aim of this study is to investigate whether intraoperative CT imaging leads to improvement of the implant position and the number of scans required to satisfy the surgeon.

## **Part II Clinical perspective**

The general aim of the studies presented in the previous part is the improvement of the workflow in orbital reconstruction using technological developments. Part III concentrates on the basics of orbital wall fracture management; indications and timing of surgery. There is no widely accepted clinical protocol that is supported by solid scientific evidence.

In **chapter 6**, an updated clinical protocol for orbital wall fractures is presented based on the current literature. In this protocol the emphasis is on nonsurgical treatment and evaluation by objective orthoptic measurements. In this two-centre, multidisciplinary, prospective, cohort study, the aim is to monitor the outcome of this updated protocol.

### **Discussion and summary**

In the general discussion (**chapter 7**), all findings are carefully reported, evaluated, and discussed, together with a vision on future studies and incentives for studies with clinical relevance. English and Dutch summaries are presented in **chapter 8**.

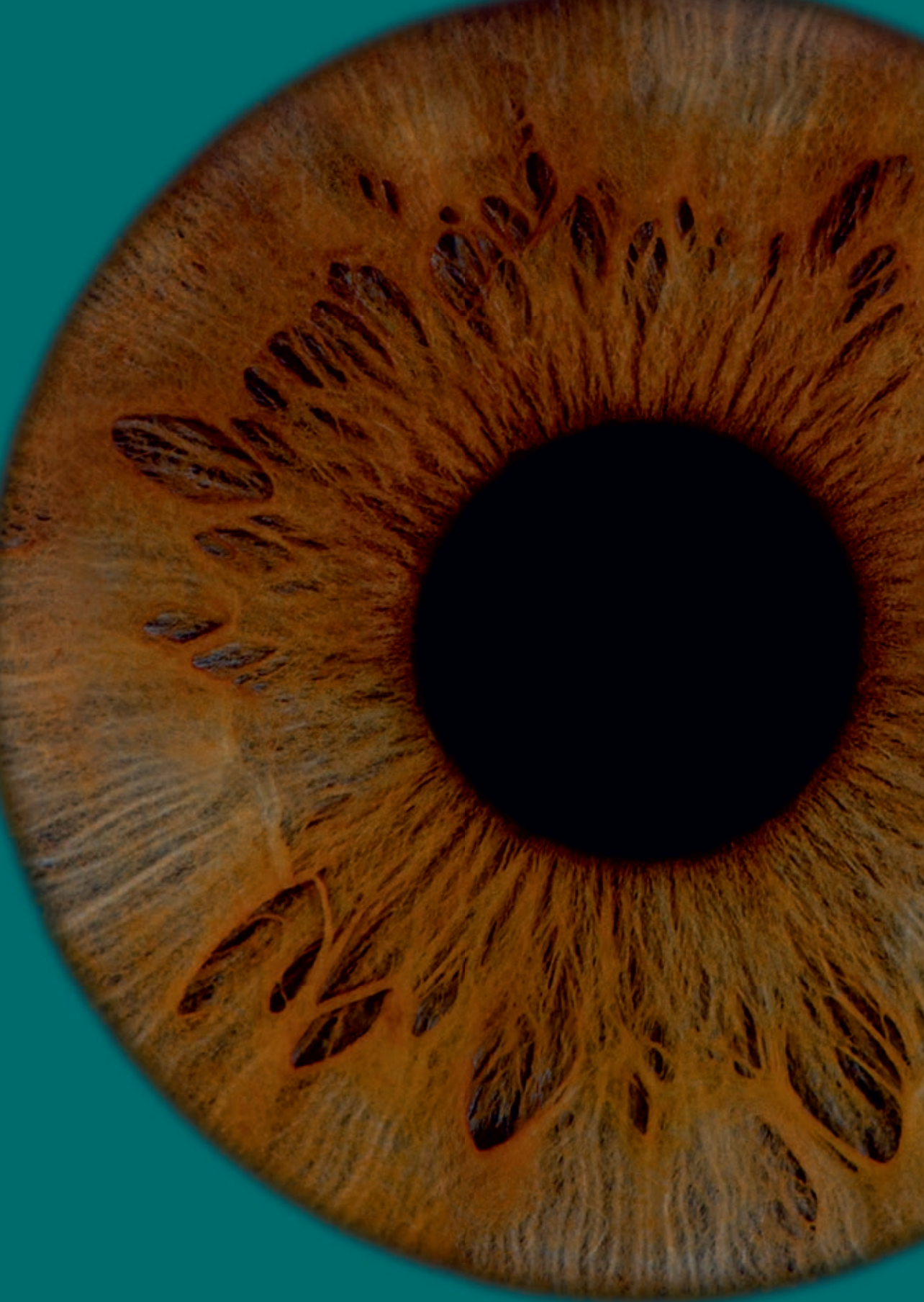

## References

1. Man K de: Orbitabodemfracturen. *Erasmus University Rotterdam, the Netherlands*. Academic dissertation, 1982
2. Koornneef L: New insights in the human orbital connective tissue: result of a new anatomical approach. *Arch Ophthalmol* 95: 1269-1273, 1977
3. Koornneef L: Current concepts on the management of orbital blow-out fractures. *Ann Plast Surg* 9: 185-200, 1982
4. Dubois L, Steenen SA, Gooris PJJ, et al.: Controversies in orbital reconstruction - I. Defect-driven orbital reconstruction: a systematic review. *Int J Oral Maxillofac Surg* 44: 308-315, 2015
5. Dubois L, Steenen SA, Gooris PJJ, et al.: Controversies in orbital reconstruction - II. Timing of post-traumatic orbital reconstruction: a systematic review. *Int J Oral Maxillofac Surg* 44: 433-440, 2015
6. Dubois L, Steenen SA, Gooris PJJ, et al.: Controversies in orbital reconstruction - III. Biomaterials for orbital reconstruction: a review with clinical recommendations. *Int J Oral Maxillofac Surg* 45: 41-50, 2016
7. Dubois L, Schreurs R, Jansen J, et al.: Predictability in orbital reconstruction: a human cadaver study. Part II: navigation-assisted orbital reconstruction. *J Craniomaxillofac Surg* 43: 2042-2049, 2015
8. Gander T, Essig H, Metzler P, et al.: Patient specific implants (PSI) in reconstruction of orbital floor and wall fractures. *J Craniomaxillofac Surg* 43: 126-130, 2015
9. Turvey TA, Golden BA: Orbital anatomy for the surgeon. *Oral Maxillofac Surg Clin North Am* 24: 525-536, 2012
10. Gospe III SM, Tariq Bhatti M: Orbital anatomy. *Int Ophthalmol Clin* 58: 5-23, 2018
11. René C: Update on orbital anatomy. *Eye* 20: 1119-1129, 2006
12. Braham HP, Ramakrishnan VR, Kingdom TT: Chapter 19 - Optic nerve decompression. In: Chiu AG, Palmer J, Adappa N (eds.), *Atlas of endoscopic sinus and skull base surgery*, 2nd edition. Philadelphia: Elsevier, 157-164, 2019
13. Bullock JD, Warwar RE, Ballal DR, Ballal RD: Mechanisms of orbital floor fractures: a clinical, experimental, and theoretical study. *Trans Am Ophthalmol Soc* 97: 87-110, 1999
14. Waterhouse N, Lyne J, Urdang M, Garey L: An investigation into the mechanism of orbital blowout fractures. *Br J Plast Surg* 52: 607-612, 1999
15. Ahmad F, Kirkpatrick NA, Lyne J, Urdang M, Waterhouse N: Buckling and hydraulic mechanisms in orbital fractures: fact or fiction? *J Craniofac Surg* 17: 438-441, 2006
16. Ellis III E: Surgical approaches to the orbit in primary and secondary reconstruction. *Facial Plast Surg* 30: 537-544, 2014
17. Al-Moraissi EA, Thaller SR, Ellis E: Subciliary vs. transconjunctival approach for the management of orbital floor and periorbital fractures: a systematic review and meta-analysis. *J Craniomaxillofac Surg* 45: 1647-1654, 2017
18. Ploder O, Klug C, Backfrieder W, et al.: 2D- and 3D-based measurements of orbital floor fractures from CT scans. *J Craniomaxillofac Surg* 30: 153-159, 2002
19. Dubois L, Jansen J, Schreurs R, et al.: How reliable is the visual appraisal of a surgeon for diagnosing orbital fractures? *J Craniomaxillofac Surg* 44: 1015-1024, 2016
20. Gooris PJJ, Muller BS, Dubois L, et al.: Finding the ledge: sagittal analysis of bony landmarks of the orbit. *J Oral Maxillofac Surg* 75: 2613-2627, 2017
21. Amin JD, Rizzi CJ, Trent G, et al.: A consistent reliable landmark to assist in placement of orbital floor reconstruction plates after blowout fractures. *J Craniofac Surg* 30: 2277-2279, 2019
22. Evans BT, Webb AAC: Post-traumatic orbital reconstruction: anatomical landmarks and the concept of the deep orbit. *Br J Oral Maxillofac Surg* 45: 183-189, 2007



23. Kim JW, Goldberg RA, Shorr N: The inferomedial orbital strut: an anatomic and radiographic study. *Ophthalmic Plast Reconstr Surg* 18: 355-364, 2002
24. Novelli G, Tonellini G, Mazzoleni F, et al.: Virtual surgery simulation in orbital wall reconstruction: integration of surgical navigation and stereolithographic models. *J Craniomaxillofac Surg* 42: 2025-2034, 2014
25. Gellrich NC, Schramm A, Hammer B, et al.: Computer-assisted secondary reconstruction of unilateral posttraumatic orbital deformity. *Plast Reconstr Surg* 110: 1417-1429, 2002
26. Schreurs R, Dubois L, Becking AG, et al.: Quantitative assessment of orbital implant position - A proof of concept. *PLoS ONE* 11: e0150162, 2016
27. Azarmehr I, Stokbro K, Bell B, et al.: Surgical navigation: a systematic review of indications, treatments, and outcomes in oral and maxillofacial surgery. *J Oral Maxillofac Surg* 75: 1987-2005, 2017
28. Young SM, Kim YD, Kim SW, et al.: Conservatively treated orbital blowout fractures. *Ophthalmology* 125: 938-944, 2018
29. Christensen BJ, Zaid W: Inaugural survey on practice patterns of orbital floor fractures for American oral and maxillofacial surgeons. *J Oral Maxillofac Surg* 74: 105-122, 2016
30. Aldekhayel S, Aljaaly H, Fouda-Neel O, et al.: Evolving trends in the management of orbital floor fractures. *J Craniofac Surg* 25: 258-261, 2014
31. Burnstine MA: Clinical recommendations for repair of isolated orbital floor fractures: an evidence-based analysis. *Ophthalmology* 109: 1207-1210, 2002
32. Scawn RL, Lim LH, Whipple KM, et al.: Outcomes of orbital blow-out fracture repair performed beyond 6 weeks after injury. *Ophthal Plast Reconstr Surg* 32: 296-301, 2016





P

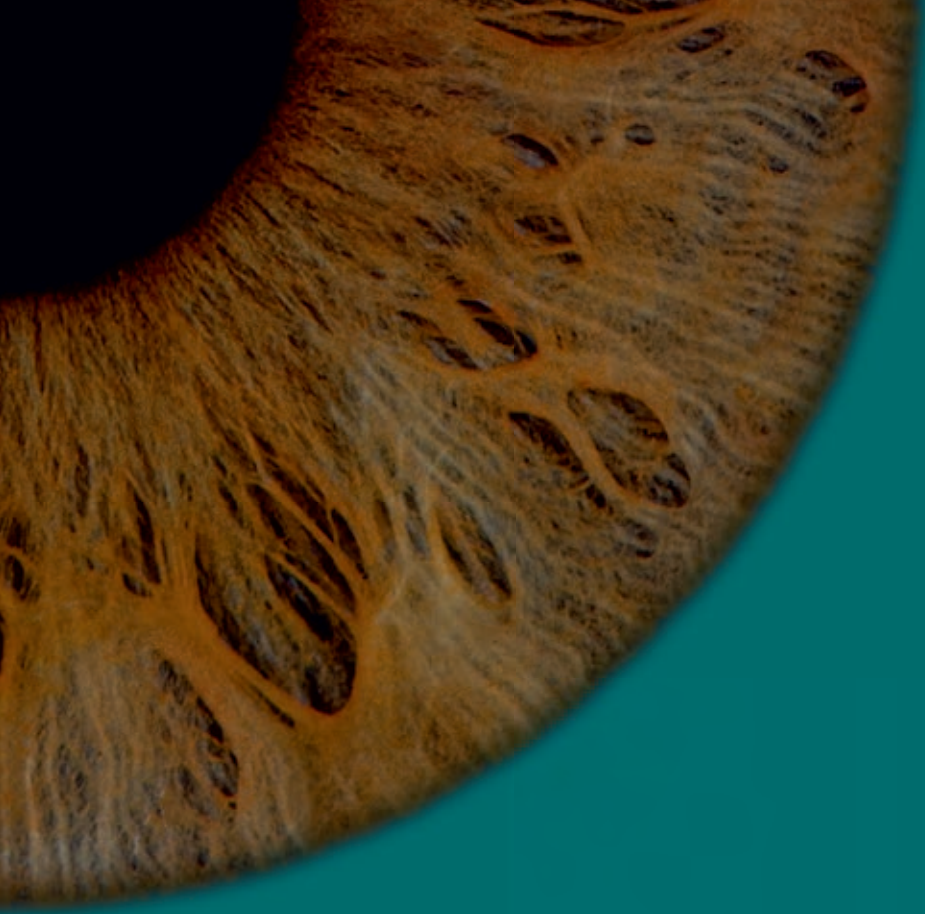
A

R

T



Technological  
advancements



C  
H  
A  
P  
T  
E  
R

2

# Validation of a semi-automatic software segmentation method to measure orbital volume

This chapter is based on the publication:  
*Orbital volume analysis: validation of a semi-automatic software segmentation method*

*J. Jansen, R. Schreurs, L. Dubois, T.J.J. Maal, P.J.J. Gooris, A.G. Becking*

*Published in:  
International Journal of Computer Assisted Radiology and Surgery, 2016*

## Abstract

**Purpose:** The purpose of this study was to validate a quick, accurate, and reproducible (semi-)automatic software segmentation method to measure orbital volume in the unaffected bony orbit. Precise volume measurement of the orbital cavity is a useful addition to preoperative planning and intraoperative navigation in orbital reconstruction.

**Materials and methods:** In 21 CT scans, one unaffected orbit was selected to compare manual segmentation (gold standard) with three segmentation methods using iPlan software (version 3.0.5; Brainlab, Feldkirchen, Germany): automatic (method A), automatic minus bone/air masks (method SA), and automatic minus masks followed by manual adjustments (method SAA). First, validation of the manual segmentation and a newly described method for the anterior boundary was performed. Subsequently the accuracy, reproducibility, and time efficiency of the methods were examined. Measurements were performed by two observers.

**Results:** The intraclass correlation for the interobserver agreement of the anterior boundary was 0.992, and the intraobserver and interobserver agreement for the manual segmentation were 0.997 and 0.994, respectively. Method A had an average volumetric difference of 0.49 cc (SD 0.74) in comparison with the gold standard; this was 0.24 cc (SD 0.27) for method SA and 0.86 cc (SD 0.27) for method SAA. The average time for each method was 38 (SD 5.4), 146 (SD 16.0), and 327 (SD 36.2) seconds per orbit.

**Conclusion:** The built-in automatic method A is quick, but suboptimal for clinical use. The newly developed method SA appears to be accurate, reproducible, quick, and easy to use. Manual adjustments in method SAA are more time-consuming and do not improve volume accuracy. The largest volume discrepancy is located near the inferior orbital fissure.

## Introduction

Reconstruction of the bony orbit is a challenge in posttraumatic orbital wall reconstruction, as well as in the treatment of orbital pathologies such as decompression surgery in Graves' orbitopathy. The orbit has a complex conical structure<sup>1,2</sup>. A blow-out fracture is usually the result of trauma to the globe and causes an increase in volume of the bony orbit. An increase of  $>2$  cc can lead to significant functional and aesthetic sequelae such as diplopia and enophthalmos<sup>3,4</sup>. Both diplopia and enophthalmos are also seen as a complication after reconstruction of orbital fractures, possibly due to suboptimal anatomical repositioning or reconstruction. An increase of 1 cc in orbital volume is believed to result in 1 mm of enophthalmos on average<sup>1,5-9</sup>. Other recognized causes of merely late enophthalmos are fat atrophy, fibrosis, and loss of periorbital support<sup>10</sup>. Regardless of the approach or choice of materials, restoration of orbital volume to improve function and aesthetics should be the main goal<sup>11</sup>. An accurate preoperative assessment of the orbital content is of importance for achieving an anatomically perfect end result<sup>12</sup>. Orbital volume measurement is a useful addition to preoperative planning for orbital reconstruction, e.g., in traumatology, pathology, or decompression surgery.

Computed tomography (CT) is the imaging modality of choice in orbital wall fractures<sup>13-17</sup>. The quality of CT scanners and reconstruction software has improved significantly over the years. This has enabled the clinician to assess the bony orbit more precisely. Despite these improvements, it is still difficult to determine the volume of the bony orbit. The orbital medial wall and orbital floor are very thin structures and their boundaries are not well defined. This is partly due to the partial volume effect<sup>18,19</sup>. The position of the anterior boundary is arguable and the posterior boundary is complex with its annulus, inferior and superior orbital fissure, and optic foramen.

Several methods to measure orbital volume have been validated over the years<sup>20</sup>. Manual segmentation, outlining the content of the bony orbit slice by slice, is accurate. Unfortunately, it is time-consuming and poorly applicable in clinical practice. In the past, software programs have been

developed, with varying results, that are able to segment the orbit (semi-) automatically using CT scans<sup>5,21-23</sup>. The clinical applicability of a method should depend on how quick, accurate, reproducible, and versatile it is<sup>24</sup>.

In this study, manual segmentation of the bony orbit, selected to be the gold standard<sup>2,20</sup>, is compared to three different methods using iPlan software (version 3.0.5; Brainlab, Feldkirchen, Germany): the automatic segmentation (method A), a semi-automatic method which combines the automatic method with subtraction of a bone ( $\geq +400$  HU) and air ( $\leq -600$  HU) density mask (method SA), and a semi-automatic method minus masks combined with manual adjustments (method SAA). The purpose of this study is to validate these (semi-)automatic segmentation methods for measuring orbital volume based on CT scans of unaffected bony orbits and investigate which method is most suitable for clinical and scientific purposes. The manual segmentation and a newly described delineation of the anterior boundary are first validated to make an accurate comparison possible. To our knowledge, the automatic orbital volume segmentation in this software has not yet been validated for orbital volume segmentation. The software possesses functionalities for preoperative planning and perioperative navigation. The validation of accurate volume analysis serves as a basis for utilising these functionalities in orbital surgery.

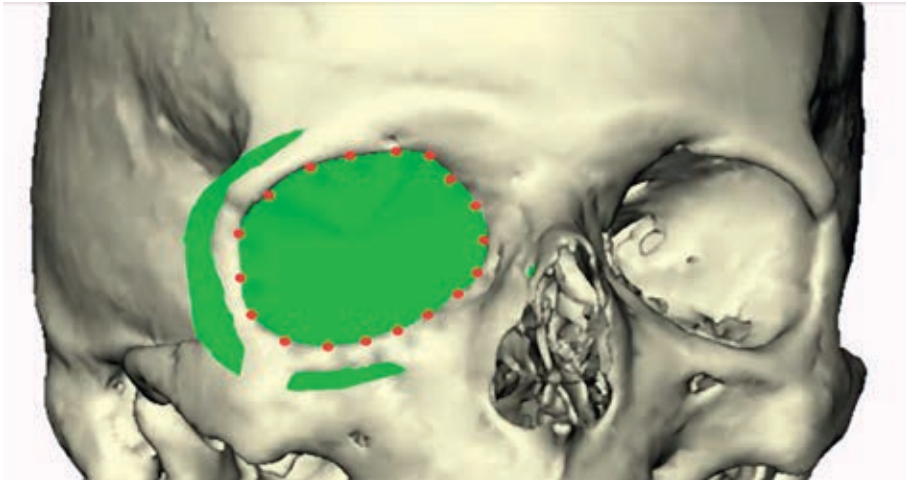
## Materials and methods

CT data of trauma patients were obtained from the Department of Oral and Maxillofacial Surgery at the Radboud University Nijmegen Medical Centre. From the database of CT scans, a total of 21 orbits, one orbit per scan, was selected. All CT scans were acquired using the standardised trauma protocol (Toshiba Aquillon ONE™): 0.5 mm slice thickness, 0.5 mm slice increment, 100-120 kV, 80-440 mA, 200-220 FOV, 0.656 Pitch, and a 512×512 image matrix. The inclusion criteria were: at least one unaffected bony orbit, no visible orbital pathology, and no blood or other body fluids in the ipsilateral sinuses.



### Anatomical boundaries

To calculate a volume in general, a virtually enclosed space is needed. In order to be able to compare the different methods, the orbital boundaries need to be defined first. The anterior boundary is reported to be difficult to define<sup>20</sup>. In this study, interobserver agreement for the anterior boundary was measured using the following method.

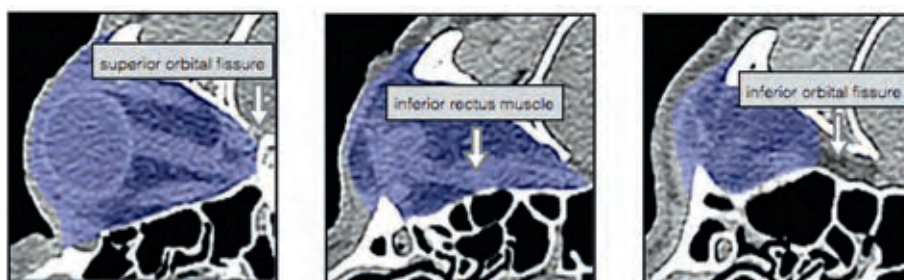


**Figure 1** The anterior plane constructed from landmark points positioned along the orbital rim.

Two observers placed landmark points along the edge of the orbital rim roughly 0.5-1.0 cm apart from each other using Maxilim software (version 2.3.0; Medicim NV, Mechelen, Belgium) as shown in Fig. 1. This was done for ten scans. The observers started at the supraorbital foramen, continued laterally over the edge of the supraorbital rim, toward the lateral orbital rim, and the inferior rim. Medially, the anterior lacrimal crest is followed upward back to the supraorbital foramen. From these indicated landmarks, a surface was reconstructed connecting all landmarks as well as the centre of gravity of these landmarks, creating the anterior plane. The anterior plane, created for each of the 21 orbits, was used as the anterior border in the manual segmentation and each of the (semi-)automatic segmentation methods. The posterior boundaries of the bony orbit were defined as the initiation of the optic foramen, inferior and superior orbital fissure.

### Gold standard

There is no consensus concerning the gold standard for orbital volume measurement. In this study, the manual segmentation of CT scans was used. Initially, the interobserver and intraobserver variability of ten orbits was measured to test the accuracy of this gold standard. Two observers segmented all ten orbits independently; one of the observers performed all segmentations twice. Digital imaging and communication in medicine (DICOM) files of the selected CT scans were imported in Matlab software (version 2012b; The Mathworks Inc., Natick, MA, USA) to perform the manual segmentation. The software used for manual segmentation showed the CT scan in an axial, coronal, and sagittal plane, as well as a three-dimensional reconstruction. The window was set to  $-200$  to  $+200$  HU to be able to distinguish the different tissues. Moving caudally, the orbital volume was segmented by tracing the orbital boundaries manually in each individual axial slice. The initial segmentation was performed in the axial slices and followed by adjustments in the coronal and sagittal direction, if necessary. The extraocular rectus muscles were traced apically to determine the posterior boundary of the apex (Fig. 2). The segmented volumes were imported in Maxilim, and a reconstruction of the segmentation was generated to obtain a virtual model of the orbital content. Excess anterior volume of the reconstructed model was removed according to the aforementioned anterior plane, and a volumetric measurement of this cleaned model was generated within the software.



**Figure 2** Axial slices of the manual segmentation (gold standard) using a small window ( $-200$  and  $+200$  HU).

### **(Semi-)automatic segmentation methods**

Three different segmentation methods were used to measure orbital volume using iPlan 3.0.5 after importing the DICOM files (Fig. 3):

1. Method A (automatic): automatic segmentation of the orbital cavity by means of the built-in functionality in the software. The automatic segmentation is established by atlas-based segmentation. This method uses prior information of training images to recognise the shape and grey levels of determined parts of the body to perform auto-segmentation<sup>25,26</sup>.
2. Method SA (semi-automatic): the automatic segmentation with subtraction of bone and air density masks. A bone mask (+400 HU or more) and air mask (-600 HU or less) were created and subtracted from the segmentation that was obtained by the automatic method.
3. Method SAA (semi-automatic with manual adjustments): the automatic method with subtraction of bone and air mask, followed by manual adjustment of large errors using the smart shaper tool and eraser (both built-in functionalities in the software). First, the position of the scan was altered so that the skull was in a true horizontal position. The window was set between -200 and +200 HU. The axial slices were quickly scanned for significant irregularities and mistakes in added voxels outside the bony orbit. Then the sagittal plane was used to delineate the inferior orbital fissure by following the inferior rectus muscle and to define the apical limit. Finally, the axial slices were scanned to make final adjustments.

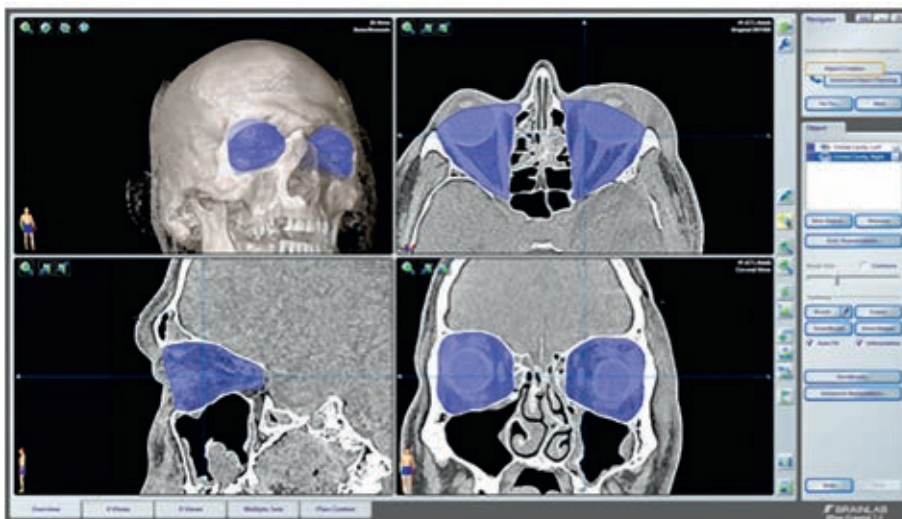
Final volume calculations were performed in Maxilim. In Maxilim, the anterior planes previously used for the manual reconstructions (gold standard) were used to remove content outside the bony orbit of the (semi-)automatic methods in order to measure the volume and compare it to the gold standard.



### Statistical analysis

The results in this article were analysed in IBM SPSS Statistics (version 22.0; IBM Corp., Armonk, NY, USA). The volumes for the anterior boundary and manual segmentation were computed and descriptive statistics, mean difference, and standard deviation (SD) were calculated. The intraclass correlation coefficient (ICC) and 95 % confidence interval (CI) were measured to test the interobserver and intraobserver agreement for the volumetric measurements for both the anterior boundary as well as the manual segmentation (gold standard).

For the (semi-)automatic segmentation methods, the correlation between the gold standard and the computed volumes of the three separate methods was analysed using the mean difference and SD. For the SAA method, both interobserver and intraobserver agreement were measured using ICC and the 95 % CI of the bony orbital volumes. The average time in seconds and SD was also calculated for all three methods. Finally, Dice coefficients and distance maps were computed to compare the (semi-)automatic methods to the gold standard. For the distance maps, the mean difference on the border of the segmentation was compared in millimetres (mm). Both mean distance measure and the 95th percentile of the absolute distance measure were measured. Differences in the data were tested using a paired *t* test.



**Figure 3** Screenshot of the automatic segmentation in iPlan 3.0.5.

## Results

### Validation of the anterior boundary

Two observers indicated the landmark points on ten CT scans. The ICC was 0.992 (95 % CI 0.956–0.998) when comparing the orbital volumes after the cut-off by the anterior planes reconstructed by the different observers for all datasets. The mean difference for the resulting volumes was 0.17 cc (SD 0.24).

### Validation of the gold standard

Two observers performed the manual segmentation for ten scans. The mean volume of all calculations was 29.9 cc (SD 2.26). The intraobserver ICC was 0.997 (95 % CI 0.987–0.999) with a mean difference of 0.09 cc (SD 0.18). The interobserver ICC was 0.994 (95 % CI 0.976–0.998) with a mean difference of 0.03 cc (SD 0.27).

### Gold standard versus three (semi-)automatic segmentation methods

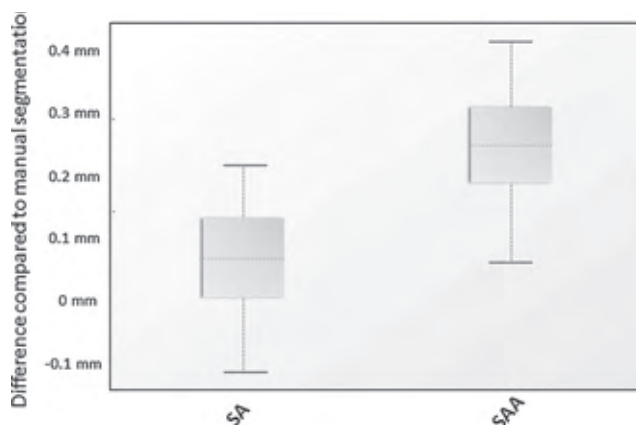
All 21 orbits were segmented to compare the gold standard to the three different methods (Table 1). Method A had a mean difference of 0.49 cc (SD 0.74) in comparison with the gold standard. The average time was 38 s (SD 5.4) per orbit. Method SA had a mean difference of 0.24 cc (SD 0.27) with the gold standard segmented orbits. The average time was 146 s (SD 16.0) per orbit. Method SAA gave a mean difference of 0.86 cc (SD 0.27) to the gold standard segmentation. The average time was 327 s (SD 36.2) per orbit. The ICC for the intraobserver variability was 0.998 (95 % CI 0.991–0.999) and the interobserver variability 0.990 (95 % CI 0.890–0.998) for method SAA.

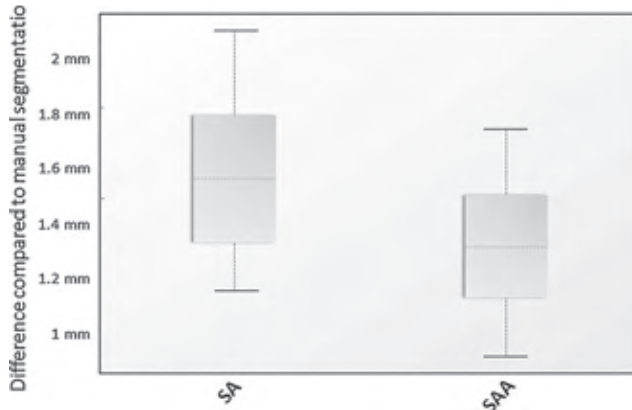


**Table 1** Results of the three (semi-)automatic methods compared to the gold standard.

	Average difference (cc)	SD (cc)	Intraobserver (ICC)	Interobserver (ICC)	Average time (s)	SD (s)
Method A	0.49	0.74	–	–	38	5.4
Method SA	0.24	0.27	–	–	146	16.0
Method SAA	0.86	0.27	0.998	0.990	327	36.2

Concerning the distance maps, the mean distance measure for method SA was 0.07 mm (SD 0.09) and for method SAA 0.24 mm (SD 0.10) compared to the gold standard. The paired  $t$  test showed a significant difference ( $p < 0.001$ ; Fig. 4). The 95th percentile of the absolute distance measure of method SA was 1.58 mm (SD 0.30) and 1.33 mm (SD 0.23) for method SAA. The SAA method showed a significantly larger difference to the gold standard segmentation than the SA method ( $p = 0.001$ ; Fig. 5). The mean Dice coefficients of method A, method SA, and method SAA each compared to the gold standard were 0.961 (SD 0.011), 0.973 (SD 0.003) and 0.979 (SD 0.003), respectively.

**Figure 4** Mean distance measure between method SA versus gold standard and method SAA versus gold standard ( $p < 0.001$ ).



**Figure 5** 95th percentile of the absolute distance measure between method SA versus gold standard and method SAA versus gold standard ( $p=0.001$ ).

## Discussion

The purpose of this study was to validate a quick, accurate, and reproducible (semi-)automatic segmentation method to measure orbital volume of unaffected bony orbits. The orbit is a complex anatomical structure, which makes it challenging to measure its volume accurately. Not only does it have thin walls, it also lacks an anterior border and has several posterior anatomical gaps. The anatomy becomes even more complex if an orbital wall is fractured. For this reason, it is important to optimise preoperative diagnostics to improve outcome after orbital reconstruction. In our opinion, accurate measurement of the orbital volume is the first step in preoperative planning.

### Anterior boundary

The anterior part of the orbit has the widest diameter and is therefore responsible for the biggest deviation in volume measurement, even with small differences in diameter estimations. In this study, a new method was validated for the anterior boundary of the bony orbit. A surface was reconstructed connecting all landmarks as well as the centre of gravity of these landmarks, creating the anterior plane. This is congruent with the description of the anterior border shape of Osaki et al.<sup>20</sup>. Our study is the first study demonstrating the accuracy and reproducibility of this

method. The anterior plane was used to separate excess volume outside the bony orbit in all segmentations in order to be able to compare them. This eliminated any doubts about volume differences at the anterior boundary.

### **Gold standard**

In the literature, two methods are suggested to be the gold standard for measuring orbital volume: slice-by-slice manual segmentation of CT scans and the use of different kinds of filling materials (beads, silicone, and water) for the enucleated orbits of cadavers<sup>20</sup>. Both methods have their advantages and disadvantages. The advantage of the manual segmentation is that only a CT scan is required to measure the volume. The disadvantage is that it still is an observer-dependent process, and therefore, it is subject to discrepancies in assessment between observers. The filling method has the advantage that a real volume is measured. The disadvantage is that it is difficult to contour the anterior border of the orbit, which means that it is practically impossible to measure the exact orbital volume. Apart from this, the method can only be used in anatomical specimen and is useless in a clinical situation. In this study, the manual segmentation method was used as the gold standard. The reproducibility of the method investigated was validated and demonstrated sufficient high correlation for both interobserver and intraobserver measurements. Trauma scans were used on purpose to mimic the clinical preoperative setting. This means that the patient was not always scanned in a well-aligned position. The agreement may have been even higher when scan data of properly aligned patients had been used.

### **(Semi-)automatic methods**

As mentioned in the introduction, 2 cc increase of orbital volume leads to 2 mm of enophthalmos on average, which is considered to be clinically significant. Accuracy and reproducibility should be well within those limits to prevent measuring errors from contributing to poor surgical outcome due to planning. In the past two decades, several (semi-)automatic software methods have been tested with varying results<sup>5,21-23</sup>. This is partly due to the differences in choice of gold standard, approach, and study design. It is difficult to compare results from these studies. A study by Deveci et al.



was one of the first to compare a three-dimensional (3D) reconstructive software program to a gold standard for direct measurements<sup>23</sup>. A filling method (alleged gold standard in that study) was compared to a 3D software program. They reported no significant volume discrepancy between the two methods, but the accuracy was not acceptable compared to findings in the recent literature. The mean volume difference was 0.93 cc (SD 1.08) and therefore insufficient for clinical use considering how this relates to enophthalmos. Regensburg et al. compared direct measurement with a CT-based method in Mimics version 9.11 to measure bony orbital volume and orbital fat/muscle volume<sup>21</sup>. This was performed on a single phantom and showed a difference of  $-0.7$  and  $+0.7$  % in fat and  $-1.5$  and  $-2.2$  % in muscle volume compared to the known volume. No statements were made on the total bony orbital volume of the phantom. Intraobserver variability was  $<5$  % for the calculations of fat volume, muscle volume, and bony orbital volume. This represents approximately 1.5 cc of total orbital volume, which can be considered a substantial measuring error. Strong et al. published very small intraoperator and interoperator errors when using Maxillo software<sup>5</sup>. However, comparison with a gold standard is lacking, so it is impossible to know if the real volume was measured.

In Method A, the built-in automatic segmentation was not accurate enough, probably due to the many morphological challenges hindering accurate segmentation. Method A was easy, fast, and reproducible. However, it often overestimated the volume as it frequently included parts of the surrounding bone, air (frontal/ethmoidal sinus), and inferior orbital fissure in the segmentation. This resulted in a mean difference of 0.49 cc (SD 0.74) compared to the gold standard. Therefore, this auto-segmentation is not advisable in a clinical setting.

In the newly developed method SA, bone and air masks were created. The method was designed to solve the problem of overestimation due to inclusion of bone and air in the segmentation. This resulted in higher accuracy, while the time needed to perform the segmentation increased only slightly. Mean difference compared to the gold standard was 0.24 cc (SD 0.27) and average time 146 s (SD 16.0). The SA method was still perfectly reproducible, because the creation of the mask is not observer dependent.

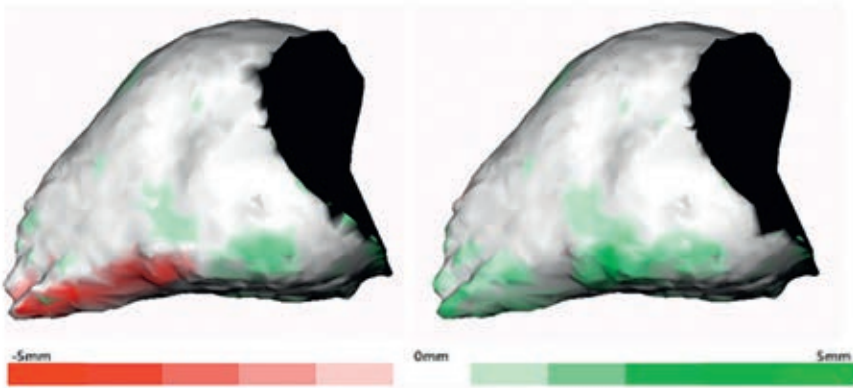


Differences in volume between the (semi-)automatic methods and the gold standard are greatly influenced by differences in defining the border of the inferior orbital fissure (Fig. 6). To overcome this repeating error within the automatic method, a manual adjustment was introduced in method SAA. It was thought that this would correct overestimation and prevent large errors. Unfortunately, it consistently produced an underestimation and had poorer accuracy with a mean difference of 0.86 cc (SD 0.27) compared to the gold standard. The reproducibility of this method was acceptable, but worse than the other two (semi-)automatic methods. Furthermore, method SAA is more time-consuming with average time of 327 s (SD 36.2). The semi-automatic method without manual adjustments proved to be accurate with an average difference of 0.24 cc (SD 0.27) compared to the gold standard.

The distance map results of the mean distance measure between method SA versus gold standard and method SAA versus gold standard illustrated that the dataset of method SA had a better general fit compared to the gold standard. The 95th percentile of the absolute distance measure of both datasets showed that method SAA had less outliers than method SA compared to the gold standard. This concludes that method SA has the best fit in comparison with the gold standard. However, it is more susceptible to large differences in specific areas than method SAA. Inspection of the distance maps showed that most outliers were situated near the inferior orbital fissure.

The results of method SAA are surprising, as one would expect that slight manual adjustments would improve method SA. The results of the distance maps and Fig. 6 for method SA show an accurate resemblance to the gold standard in most regions. The only region that is different is the region around the inferior orbital fissure, where a volume increment is seen in the SA model. The distance map of method SAA (Fig. 6) corresponds to that of method SA, except for the inferior orbital fissure, which now shows a volume decrement compared to the gold standard. An underestimation of the total volume was seen in method SAA for both observers, probably due to overcorrection of the orbital contour by the use of the built-in smart shaper tool and difficulty to find the border of the orbital volume

and inferior orbital fissure. The smart shaper tool intelligently facilitates recontouring of the segmented volume in 3D by working on a 2D slice. This saves time, as not every slice has to be altered one at the time. However, this probably caused the overcorrection as alterations were made to other slices without accurate control<sup>27</sup>.



**Figure 6** Distance maps of method SA (*left*) and method SAA (*right*) projected on the gold standard segmentation; *red* illustrates excess and *green* deficiency in volume of the (semi-) automatic methods compared to gold standard.

The Dice coefficients of all three methods compared to the gold standard are excellent with method SAA being slightly better than method SA. The outliers in method SA described earlier might explain this. Method SAA showed a slightly better overlap between the segmentation by means of the Dice coefficient. Nevertheless, method SA proves to be superior considering the volume accuracy, reproducibility, and time efficiency compared with a high Dice coefficient.

## Conclusion

In conclusion, in this study a manual segmentation, anterior boundary and three methods using iPlan 3.0.5 were validated for the unaffected bony orbit. The results showed that method SA (automatic segmentation with

subtraction of bone and air density masks) can be highly recommended based on the results of the study. This method proved to be accurate, reproducible, quick, and easy to use. The automatic segmentation option should only be used in combination with educated inspection afterward. This is mainly because of errors due to automatically adding volume of bony and pneumatized areas, as well as added volume of the inferior orbital fissure.

The accuracy of orbital reconstructive surgery will benefit from improvements in diagnostics and planning using three-dimensional (3D) software. Apart from experience and surgical skills, outcomes of orbital reconstruction depend on careful and precise measurements and planning in the preoperative assessment, intraoperative navigation, and intraoperative radiography. Method SA could provide better preoperative assessment and might therefore result in fewer complications and less need for secondary reconstructions.

The researchers are aware that many additional aspects, such as posttraumatic and iatrogenic fat atrophy, fibrosis, and adhesions may affect the outcome of orbital surgery. It is believed to be possible to exactly restore the volume of the bony orbit, but changes in the orbital content may compromise the final result. Nevertheless, the extent of these factors is difficult to analyse without adequate orbital volume measurements. In preoperative assessment, correct and accurate orbital volume calculation should be part of diagnosing orbital pathology and (virtual 3D) planning of orbital reconstructions. A next challenge is volume segmentation in patients with an orbital fracture. Future steps may be segmentation and manipulation, e.g. implementation of mirroring of the unaffected contralateral orbit. Further studies are being performed to validate the benefits of these new methods.

## References

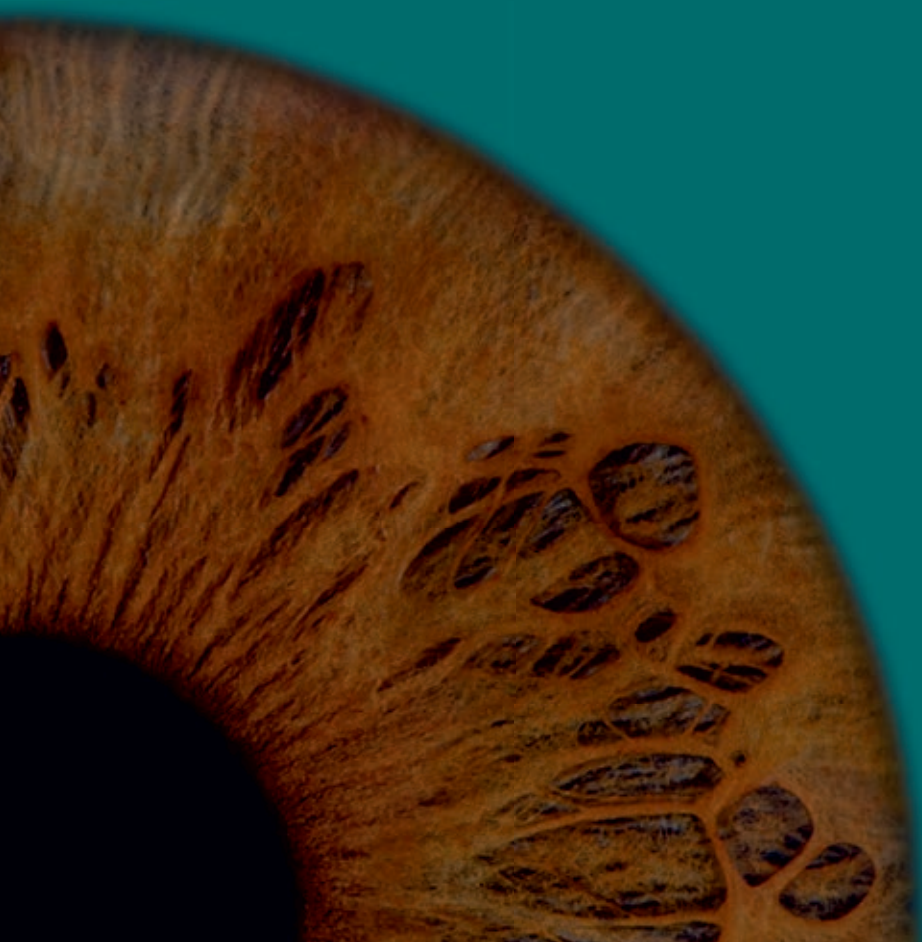1. Ramieri G, Spada MC, Bianchi SD, et al.: Dimensions and volumes of the orbit and orbital fat in posttraumatic enophthalmos. *Dentomaxillofac Radiol* 29: 302-311, 2000
2. Cooper WC: A method for volume determination of the orbit and its contents by high resolution axial tomography and quantitative digital image analysis. *Trans Am Ophthalmol Soc* 83: 546-609, 1985
3. Migliori ME, Gladstone GJ: Determination of the normal range of exophthalmometric values for black and white adults. *Am J Ophthalmol* 98: 438-442, 1984
4. Koo L, Hatton MP, Rubin PA: When is enophthalmos "significant"? *Ophthal Plast Reconstr Surg* 22: 274-277, 2006
5. Strong EB, Fuller SC, Chahal HS: Computer-aided analysis of orbital volume: a novel technique. *Ophthal Plast Reconstr Surg* 29: 1-5, 2013
6. Whitehouse RW, Batterbury M, Jackson A, et al.: Prediction of enophthalmos by computed tomography after "blow out" orbital fracture. *Br J Ophthalmol* 78: 618-620, 1994
7. Raskin EM, Millman AL, Lubkin V, et al.: Prediction of late enophthalmos by volumetric analysis of orbital fractures. *Ophthal Plast Reconstr Surg* 14: 19-26, 1998
8. Lee JW, Chiu HY: Quantitative computed tomography for evaluation of orbital volume change in blow-out fractures. *J Formos Med Assoc* 92: 349-355, 1993
9. Fan X, Li J, Zhu J, et al.: Computer-assisted orbital volume measurement in the surgical correction of late enophthalmos caused by blowout fractures. *Ophthalmic Plast Reconstr Surg* 19: 207-211, 2003
10. Clauser L, Galiè M, Pagliaro F, et al.: Posttraumatic enophthalmos: etiology, principles of reconstruction, and correction. *J Craniofac Surg* 19: 351-359, 2008
11. Dubois L, Steenen SA, Gooris PJJ, et al.: Controversies in orbital reconstruction - I. Defect-driven orbital reconstruction: a systematic review. *Int J Maxillofac Surg* 44: 308-315, 2015
12. Gellrich NC, Schramm A, Hammer B, et al.: Computer-assisted secondary reconstruction of unilateral posttraumatic orbital deformity. *Plast Reconstr Surg* 110: 1417-1429, 2002
13. Betts AM, O'Brien WT, Davies BW, et al.: A systematic approach to CT evaluation of orbital trauma. *Emerg Radiol* 21: 511-531, 2014
14. Hardt N, Kuttnerberger J: Radiology of craniofacial fractures. In: *Craniofacial trauma: Diagnosis and management*, 1st edition Springer, Berlin, 15-31, 2010
15. Forbes G, Gehring DG, Gorman CA, et al.: Volume measurements of normal orbital structures by computed tomographic analysis. *AJR Am J Roentgenol* 145: 149-154, 1985
16. Manson PN, Grivas A, Rosenbaum A, et al.: Studies on enophthalmos: II. The measurement of orbital injuries and their treatment by quantitative computed tomography. *Plast Reconstr Surg* 77: 203-214, 1986
17. Charteris DG, Chan CH, Whitehouse RW, et al.: Orbital volume measurement in the management of pure blowout fractures of the orbital floor. *Br J Ophthalmol* 77: 100-102, 1993
18. Noser H, Hammer B, Kamer L: A method for assessing 3D shape variations of fuzzy regions and its application on human bony orbits. *J Digit Imaging* 23: 422-429, 2010
19. Bartling SH, Majdani O, Gupta R, et al.: Large scan field, high spatial resolution flat-panel detector based volumetric CT of the whole human skull base and for maxillofacial imaging. *Dentomaxillofacial Radiol* 36: 317-327, 2007
20. Osaki TH, de Castro DK, Yabumoto C, et al.: Comparison of methodologies in volumetric orbitometry. *Ophthal Plast Reconstr Surg* 29: 431-436, 2013
21. Regensburg NI, Kok PHB, Zonneveld FW, et al.: A new and validated CT-based method for the calculation of orbital soft tissue volumes. *Invest Ophthalmol Vis Sci* 49: 1758-1762, 2008
22. Koppel DA, Foy RH, McCaul JA, et al.: The reliability of "Analyze" software in measuring orbital volume utilizing CT-derived data. *J Craniofacial Surg* 31: 88-91, 2003



## Chapter 2

23. Deveci M, Oztürk S, Sengezer M, et al.: Measurement of orbital volume by a 3-dimensional software program: an experimental study. *J Oral Maxillofac Surg* 58: 645-648, 2000
24. Bijlsma WR, Mourits MP: Radiologic measurement of extraocular muscle volumes in patients with Graves' orbitopathy: a review and guideline. *Orbit* 25: 83-91, 2006
25. Simmat I, Georg P, Georg D, et al.: Assessment of accuracy and efficiency of atlas-based autosegmentation for prostate radiotherapy in a variety of clinical conditions. *Strahlenther Onkol* 188: 807-815, 2012
26. Daisne J, Blumhofer A: Atlas-based automatic segmentation of head and neck organs at risk and nodal target volumes : a clinical validation. *Radiation Oncology* 8: 154(1-11), 2013
27. Gander T, Essig H, Metzler P, et al.: Patient specific implants (PSI) in reconstruction of orbital floor and wall fractures. *J Craniomaxillofac Surg* 43: 126-30, 2015







CHAPTER  
3

# The use of virtual mirroring during preoperative planning of an orbital reconstruction

This chapter is based on the publication:  
*Should virtual mirroring be used in the preoperative planning of an orbital  
reconstruction?*

*J. Jansen, L. Dubois, R. Schreurs, P.J.J. Gooris, T.J.J. Maal, L.F. Beenen,  
A.G. Becking*

*Published in:  
Journal of Oral and Maxillofacial Surgery, 2018*

## Abstract

**Purpose:** Mirroring has been used as a diagnostic tool in orbital wall fractures for many years, but limited research is available proving the assumed symmetry of the orbits. The purpose of this study was to evaluate volume and contour differences between orbital cavities in healthy humans.

**Materials and methods:** In this cross-sectional study, the left and right orbital cavities of a consecutive sample of patients' computed tomograms were measured. Inclusion criteria were patients with no sign of orbital or sinus pathology or fracture. Outcome variables were differences in volume and contour. Descriptive statistics and paired *t* test were used for data analysis of orbital volume and distance maps were used for analysis of orbital contour.

**Results:** The sample was composed of 100 patients with a mean age of 57; 50 % were men. The total mean orbital volume was  $27.53 \pm 3.11$  mL. Mean difference between cavities was  $0.44 \pm 0.31$  mL or 1.59 % (standard deviation [SD] 1.10 %). The orbital contour showed high similarity, with an absolute mean left-versus-right difference of 0.82 mm (SD 0.23 mm).

**Conclusion:** The authors hypothesise that the measured differences between right and left orbital volumes and contours are clinically minor. In consequence, the use of mirroring tools as part of preoperative planning in orbital reconstruction is legitimate with the aim of simulating the pretraumatised anatomy.

## Introduction

Clinical decision making in the management of orbital wall fractures is challenging because of existing controversies<sup>1-3</sup>. Diagnostics are important in assessing the severity of the fracture. Owing to the loss of bony support, the orbital volume increases and the potential result is that the orbital contents protrude into adjacent spaces. This can cause functional and aesthetic sequelae, such as diplopia and enophthalmos<sup>4</sup>. The increase in volume after orbital fractures is considered the main cause of posttraumatic enophthalmos, especially if the fracture is located in the posterior part of the orbital floor or medial wall<sup>5,6</sup>. In severe cases, it is necessary to perform an orbital reconstruction. The objective is to reconstruct the bony contours, restore the orbital anatomy and, hence, decrease the increased orbital volume, support the globe, and optimise function<sup>7</sup>.

Orbital surgery is difficult because the pyramidal shape of the cavity causes limited access, poor visibility, and potential complications. Technological developments in the planning and execution of treatment have led to a more accurate and predictable surgical outcome<sup>8-10</sup>. Computer-assisted surgery (CAS) has proved to be a helpful tool to support the surgeon in diagnostics and treatment<sup>11-13</sup>. The surgeon can assess the severity of the fracture by collecting digital data, virtually plan the operation, and use navigation during surgery without additional radiation exposure for the patient. It improves the accuracy of the reconstruction and can shorten the operation time for orbital wall repair.

The diagnostic and preoperative phase is fundamental in the process of CAS. Several years ago, a virtual mirroring technique was introduced and has been frequently applied in diagnostics and virtual planning. Segmentation of the unaffected side and mirroring it as an overlay over the affected side produces easy-to-understand information on the dislocated bony fragments and creates an ideal virtual template for reconstruction<sup>14-16</sup>. The idea behind the tool is that the unaffected side is a good representation of the pretraumatised state of the affected side. Several studies have reported that most people have close to perfect symmetry in general<sup>17-19</sup>.

In orbital wall reconstruction, mirroring tools are often used with the assumption that the orbital cavities are an identical mirror image in volume and contour. This is one of the pillars of treatment planning. However, there is limited evidence on the extent to which contralateral orbital volumes and contours are identical. The purpose of this study was to assess the level of asymmetry in human unaffected orbits. The authors hypothesised that only minor asymmetry would exist in contralateral orbital cavities, which would support the rationale for using the mirroring technique. The specific aims of the study were to identify differences in volume and contour of the left and right bony orbits.

## **Materials and methods**

### **Study design and sample**

The authors designed and implemented a cross-sectional study to address the research question. The local ethics committee considered this study not subject to consent and the study was performed in accordance with the Declaration of Helsinki. A consecutive sample of patients was derived from a database of the Department of Radiology at the Academic Medical Centre (Amsterdam, the Netherlands). The study population was composed of adults who had undergone computed tomography (CT) examination of the brain without contrast in 2014 and 2015 for reasons other than orbital or sinus fracture or pathology. Scans were excluded when there were movement artefacts or when the facial skeleton was not completely visualised. The acquired CT scans (Siemens Sensation 64, Siemens Healthcare, Forchheim, Germany; Philips Brilliance 64, Philips Medical System, Best, the Netherlands) had a 0.75- to 1.0-mm slice thickness (512×512 matrix), 1.0-mm slice increment, 120 kV, 380 mAs, 0° gantry tilt, hard-tissue convolution kernel of H60s, and a window of W1600 and L400.

### **Study variables**

The predictor variable was the orbital cavity. The left orbital cavity was compared with the right orbital cavity. The primary outcome variables were orbital volume and the contour of the orbital cavity. The other variables were age and gender.

## Data collection

### *Orbital Volume*

Digital imaging and communications in medicine (DICOM) data of the CT scans were imported in iPlan 3.0.5 software (Brainlab, Feldkirchen, Germany). The software presents the data in multiplanar views and a three-dimensional (3D) reconstruction by volume rendering. To calculate the orbital volume, the previously validated semi-automatic method described by Jansen et al. was used<sup>20</sup>. The built-in auto-segmentation tool offers the possibility of segmenting the left and right orbital volumes (Fig. 1). From this auto-segmentation of the orbital volumes, bone and air density masks were subtracted. Subsequently, the stereolithographic (STL) files of the volumes were imported in Maxilim 2.3.0 (Medicim NV, Mechelen, Belgium). The anterior orbital plane was used to remove excess anterior volume in all orbits. Landmark points were placed along the edge of the orbital rim every 0.5 to 1.0 cm. Then, the points were connected and the centre of gravity of these landmarks was calculated. The surface that was created in this way was used as the anterior plane (Fig. 2). The anterior plane was validated in a previous study<sup>20</sup>. The final orbital volume was measured in Maxilim.

### *Orbital Contour*

In addition to differences in orbital volumes, the orbit contours were compared. For every patient, the DICOM files and STL model of the left orbital volume were mirrored. The original and mirrored CT scans and the STL files of the right and mirrored left orbital volumes were imported in Maxilim 2.3.0. The reconstructed mirrored skull was matched to the original skull with the use of voxel-based matching of the cranial base. This matching method, which superimposes the two DICOM sets based on the Hounsfield units of the voxels, has proved to be accurate and valid in several studies<sup>21,22</sup>. In addition, the mirrored left orbital volume was projected over the right orbital volume to create a distance map (Fig. 3). The distance maps were created for the orbital floor and medial wall and illustrate the 3D contour difference between the left and right orbital cavities<sup>23</sup>.

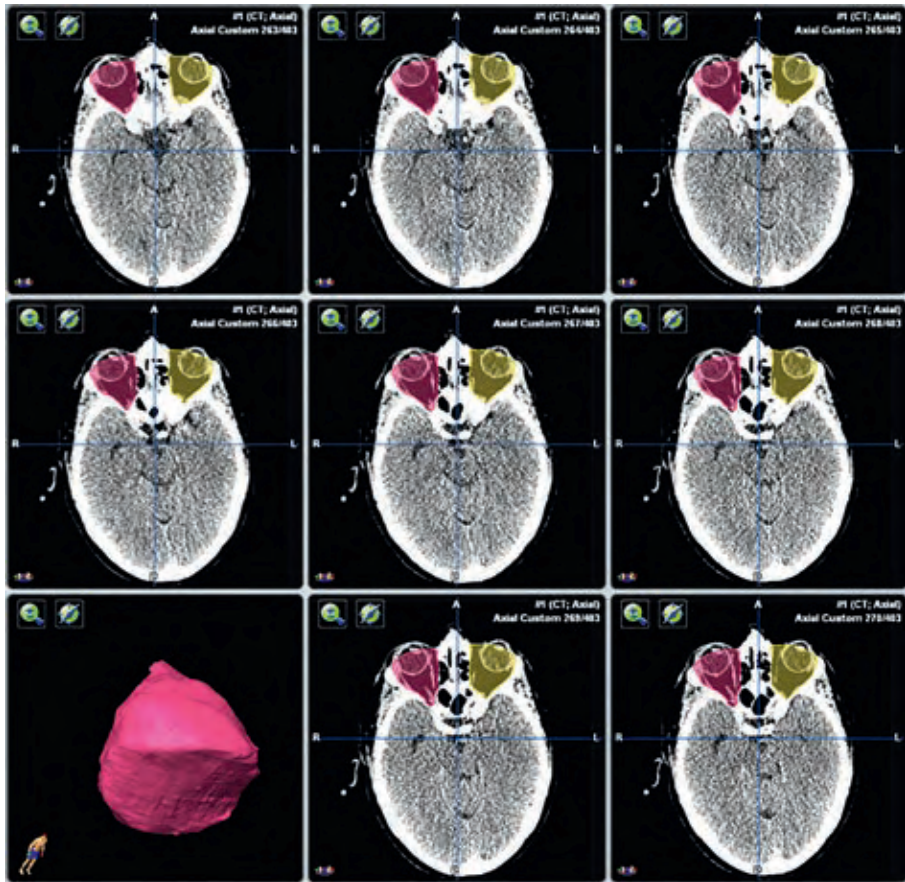
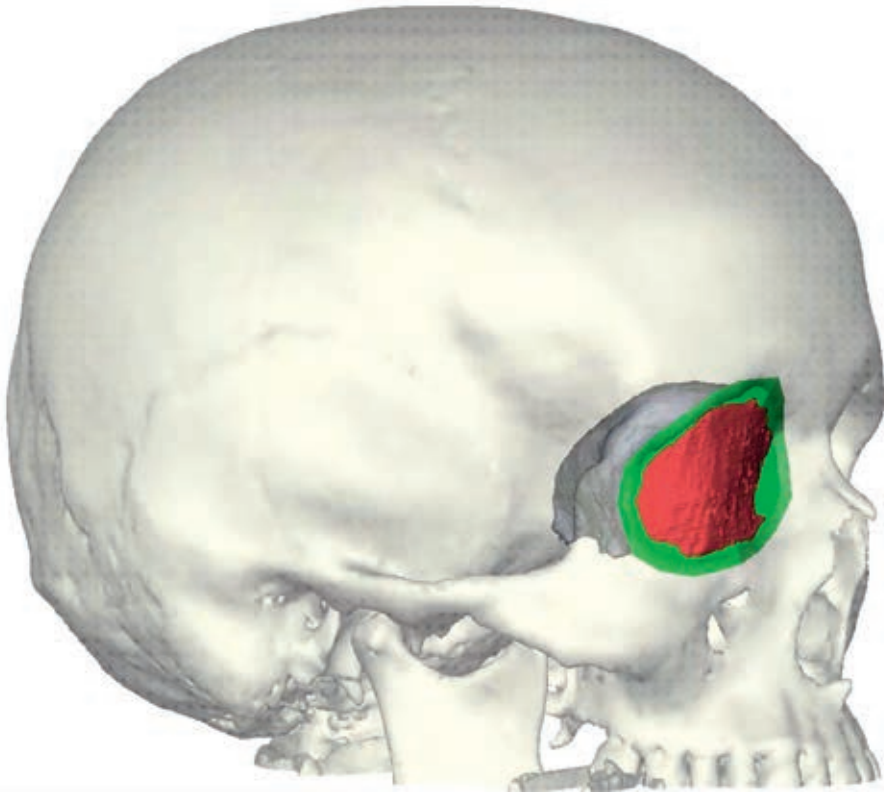
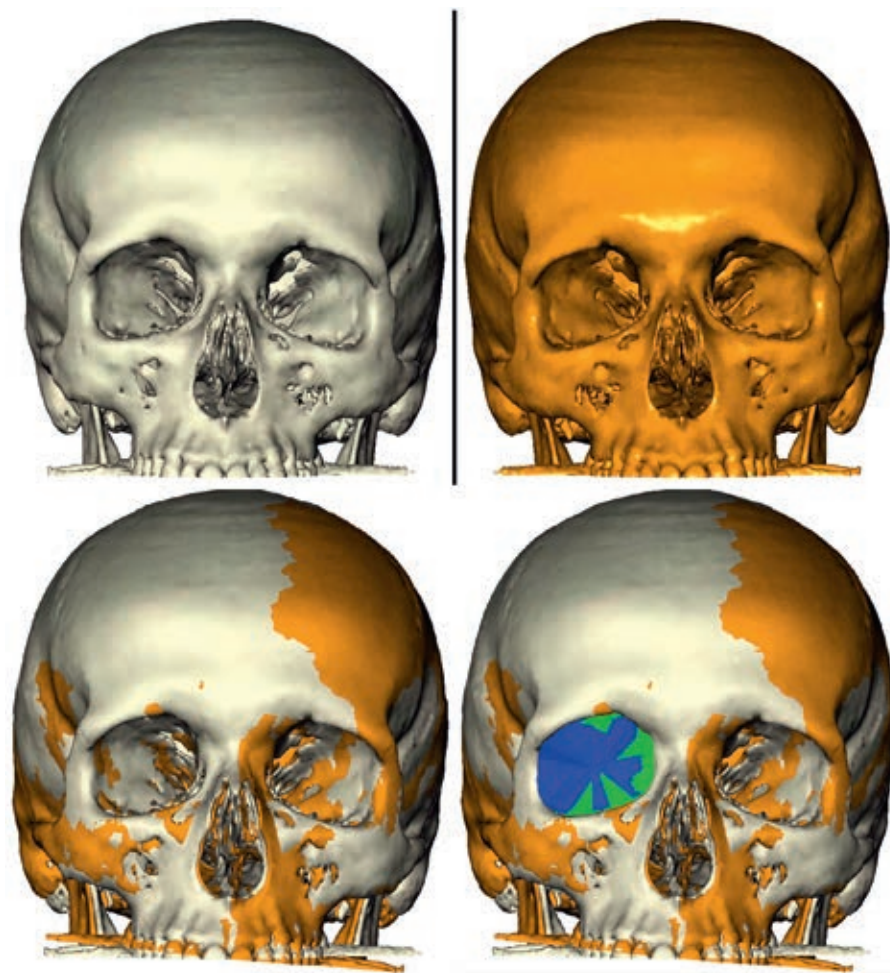


Figure 1 Auto-segmentation of the orbital cavities as a first step in measuring the orbital volume.



3

**Figure 2** The removal of excess anterior orbital volume (*red*) cut by the anterior plane (*green*) and the final orbital volume (*purple*).



**Figure 3** The creation of the distance maps by superimposing the mirrored skull (*orange*) onto the original skull (*grey*). The mirrored left orbital volume (*green*) is subsequently mirrored onto the original right volume (*blue*).

### Data analysis

The volumes of all left and right orbits were compared using descriptive statistics (mean difference and standard deviation). Differences and correlations of orbital cavity volumes were tested using paired *t* test. Variability in gender was tested with independent samples *t* test. Furthermore, the mean difference of the outer surface of the segmentation was compared in millimetres. The mean distance and



the 95th percentile of the absolute distance were measured. Analyses were performed in IBM SPSS Statistics 22.0 (IBM Corp, Armonk, NY). A *p* value less than 0.05 was considered statistically significant.

## Results

The study sample was composed of 50 men and 50 women who had a mean age of 57 years (SD 18 yr.; range, 18 to 93 yr.).

### Orbital volume

The mean orbital volume of the 200 orbits was  $27.53 \pm 3.11$  mL. The mean volume of the right orbital cavity was  $27.56 \pm 3.11$  mL and the mean volume of the left orbit was  $27.50 \text{ mL} \pm 3.13$  mL. The mean absolute difference between the right and left cavities was  $0.44 \pm 0.31$  mL. The maximum absolute volume difference was 1.65 mL or 5.81 %. The minimum orbital volume was 20.20 mL and the maximum orbital volume was 37.55 mL. The paired *t* test showed a high correlation (0.985) and no significant difference between the left and right orbital volumes ( $p=0.34$ ; Table 1).

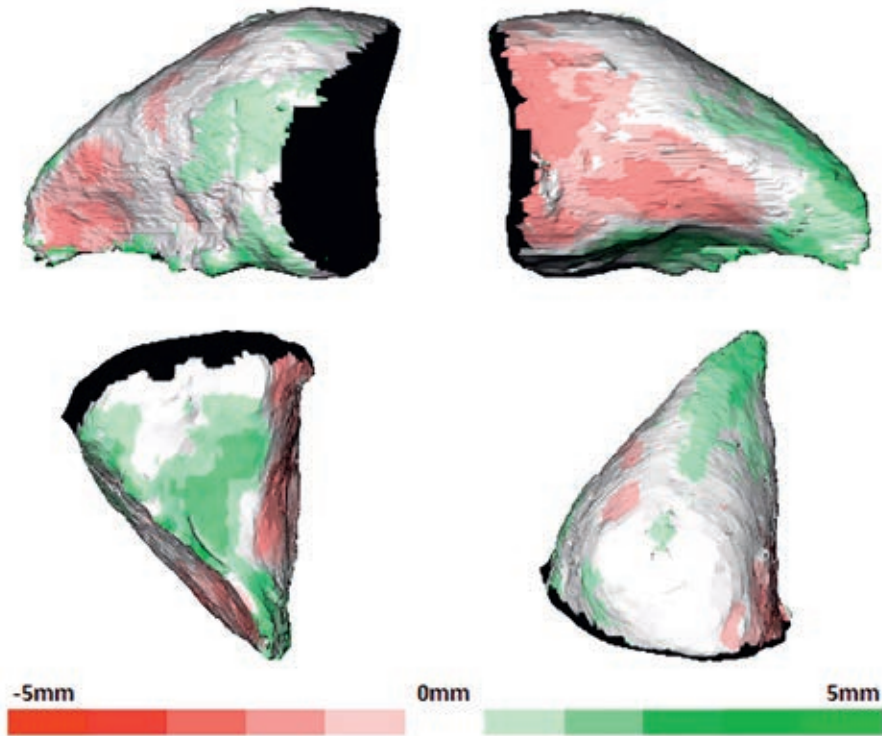
**Table 1** Mean, standard deviation (SD), minimum, and maximum of left and right orbital cavity total volumes and volume differences.

Total	Mean	SD	Minimum	Maximum
Right orbital volume (mL)	27.56	3.11	20.20	36.83
Left orbital volume (mL)	27.50	3.13	20.80	37.55
Absolute volume difference (mL)	0.44	0.31	0.00	1.65
Volume difference (%)	1.59	1.10	0.00	5.81

The mean volumes for men and women were  $28.82 \pm 3.12$  and  $26.29 \pm 2.56$  mL for the right orbital cavity and  $28.74 \pm 3.22$  and  $26.27 \pm 2.52$  mL for the left orbital cavity, respectively. Orbital cavities in men were significantly ( $p<0.05$ ) larger than those in women (Table 2). There was no significant difference ( $p=0.59$ ) in left-versus-right absolute volume between men and women.

**Table 2** Mean, standard deviation (SD), minimum, and maximum of left and right orbital cavity total volumes and volume differences by gender.

	Men		Women	
	Mean	SD	Mean	SD
Right orbital volume (mL)	28.82	3.12	26.29	2.56
Left orbital volume (mL)	28.74	3.22	26.27	2.52
Absolute volume difference (mL)	0.45	0.36	0.42	0.25
Volume difference (%)	1.58	1.25	1.61	0.94



**Figure 4** Lateral, medial, bottom, and top views of the average distance map of left-versus-right differences of the orbital contour (colour intensity illustrates the degree of average difference in millimetres).

## Discussion

The purpose of this study was to assess left-versus-right differences in orbital volume and contour. Small variations in symmetry of the face were expected<sup>17,18,24</sup>. Only when an asymmetry develops past a certain threshold does it become noticeable and potentially aesthetically disturbing<sup>25</sup>. Restoration of orbital contours is important for functional and aesthetic reasons. Orbital asymmetry can cause eye movement disorders and a disharmonious facial appearance<sup>26</sup>. The results of this study verify the use of the contralateral unaffected orbital cavity as guidance for further treatment. The authors found that the measured differences between the right and left orbital volumes and contours were clinically minor.

The left-versus-right differences in orbital volume were small in nearly all 100 patients. The mean absolute volume difference of  $0.44 \pm 0.31$  mL represents less than 2 % of the total volume. In 96 % of patients, the left-versus-right difference was less than 1 mL. The literature states that a 2 to 3 mL increase in bony orbital volume can result in a clinically visible enophthalmos of 2 to 3 mm on average<sup>27,28</sup>. Given these small variations in volume, the unaffected contralateral bony orbit in healthy humans is considered an acceptable reference in orbital reconstruction.

Of 100 patients, only four showed a left-versus-right difference larger than 1 mL; the largest difference was 1.65 mL. These asymmetries of the facial bones were visible in the three-dimensional reconstruction of the CT scans. This was due to a smaller contour of the orbital rim or differences in the anteroposterior position of the orbital rim, resulting in a smaller pyramidal base of the orbital cavity. In such a case and when an orbital floor or medial wall fracture is present, the surgeon should be able to notice this pre-existing asymmetry. In this case, the mirroring method should be used with caution, paying more attention to the anatomy of the fractured side. If these larger asymmetries go unnoticed in surgical cases, they could be responsible for postoperative enophthalmos or exophthalmos.

There was no relevant difference in symmetry between men and women. The absolute volumetric difference and standard deviation were comparable ( $p=0.59$ ) in men and women. The only notable and expected difference was that, on average, men had markedly larger bony orbits than women.

In addition to asymmetry in orbital volume, the orbital contour was studied. To achieve a pretraumatised anatomy after orbital reconstruction, it is important to restore the contour for correct support of the soft tissue. The thin shell structure of the orbital floor and medial wall consists of many curves and angles, where left-versus-right differences might exist<sup>29</sup>. The absolute mean difference in the study population was 0.83 mm (95th percentile, 1.91 mm). This proves that differences do occur in the anatomy of the orbital walls. Inspection of the distance maps showed that variations in symmetry are not centred on a specific part of the orbital wall, but rather are spread out across the entire orbital cavity. However, when analysing the individual distance maps, the apex usually showed differences.

Previous studies have presented left-versus-right differences of up to 8 % in volume (average up to 3.5 %; Table 3)<sup>30-32</sup>. In the authors' opinion, this might not be representative for a normal human population. The results could be caused by inaccuracy of the measuring technique or the small study. Kamer et al. stated that there is a major interindividual shape and size variability in the orbital floor<sup>33</sup>. In another study on interindividual morphologic differences, Kamer et al. stated that there was no relevant volume laterality between left and right orbits, which is comparable to the present results<sup>34</sup>. In 14 % of patients, left and right differences were larger than 1 mL. This is greater than the 4 % found in the present study. In general, the results of this study seem to agree with the literature for contour and volume.

In this study, no manual segmentation of the orbital volume was performed, because this is labour intensive and time-consuming. Instead, a semi-automatic software segmentation method was used. This method was previously validated and was considered accurate, reproducible, and efficient<sup>20</sup>.

**Table 3** Average and maximum volume differences in present study compared with other studies.

	n	Average difference		Maximum difference	
		mL	%	mL	%
<b>Present study</b>	100	0.44	1.6	1.65	5.8
<b>Alinasab et al.<sup>32</sup></b>	18	0.55	2.5	1.4	6.6
<b>Forbes et al.<sup>30</sup></b>	21	0.43	1.8	1.95	8.0
<b>Felding et al.<sup>31</sup></b>	11	0.77	3.1	1.91	8.7

It should be noted that in this study distance maps were created by mirroring the complete skull and matching the skull and the orbital volumes using voxel-based matching of the cranial base<sup>21,22</sup>. This method was chosen because it is extremely difficult to identify a true median plane to mirror the orbital volume<sup>35,36</sup>. It is difficult to point out exactly where the differences in the bony contour occur. In a clinical setting, it is often necessary to perform manual adjustments to achieve a good overlay of the mirrored orbital cavity on the unaffected side.

Mirroring can be performed only in patients presenting with unilateral pathology. In most cases, deformities or injuries are unilateral. Nevertheless, for bilateral pathology or trauma, it is possible to use an average orbital contour by importing an STL model of an orbit and adjusting it to patient-specific conditions.

Perfect restoration in symmetry does not necessarily result in a desired clinical outcome, and a suboptimal anatomic reconstruction does not by definition produce bad functional results. In addition to volume and contour, disorganisation of the orbital soft tissue (e.g., fat atrophy or muscle adhesions) is an important third factor in the final functional and aesthetic outcome<sup>7,37,38</sup>. Nonetheless, as shown by the literature, segmentation and mirroring tools are an important starting point for diagnostics and for planning a perfect orbital reconstruction.

The present study has some limitations. The 100 CT scans used for this study were obtained from patients examined in one hospital. Control for ethnicity was not incorporated in this study, so the sample might not be representative of a general population. Because of the nature of the study,



exophthalmometry of the patients was not possible. In future studies, it might be interesting to relate orbital volume to exophthalmometry.

The results of this study show that the unaffected contralateral orbital cavity can be used as a starting point for orbital reconstruction. The mirroring tool is a legitimate first step in planning, provided the facial skeleton is carefully examined for pre-existing asymmetries and bearing in mind the small variations in symmetry that might be present. This tool is useful in a clinical setting for preoperative planning and to check the result of the surgical reconstruction. It supplies the surgeon with essential information on the reconstruction of the orbital defect, with or without the use of an implant.

Left-versus-right differences in volume in unaffected human orbital cavities are small, with a mean difference of 0.44 mL, corresponding to 1.6 % of the total volume of the orbit. Compared with other studies, the differences are similar or slightly less in volume. The overall symmetry seems to be accurate. Based on these limited variations in orbital volume and contour, the use of the mirroring technique for orbital reconstruction in unilateral affected orbits is legitimate. This makes it a valuable first step in preoperative planning as part of CAS. However, although accurate restoration of orbital volume is a primary goal, posttraumatic changes of orbital soft tissue can still affect the final aesthetic and functional outcome. Future studies should focus on the advantages of this mirroring technique for clinical outcome and complication rates.

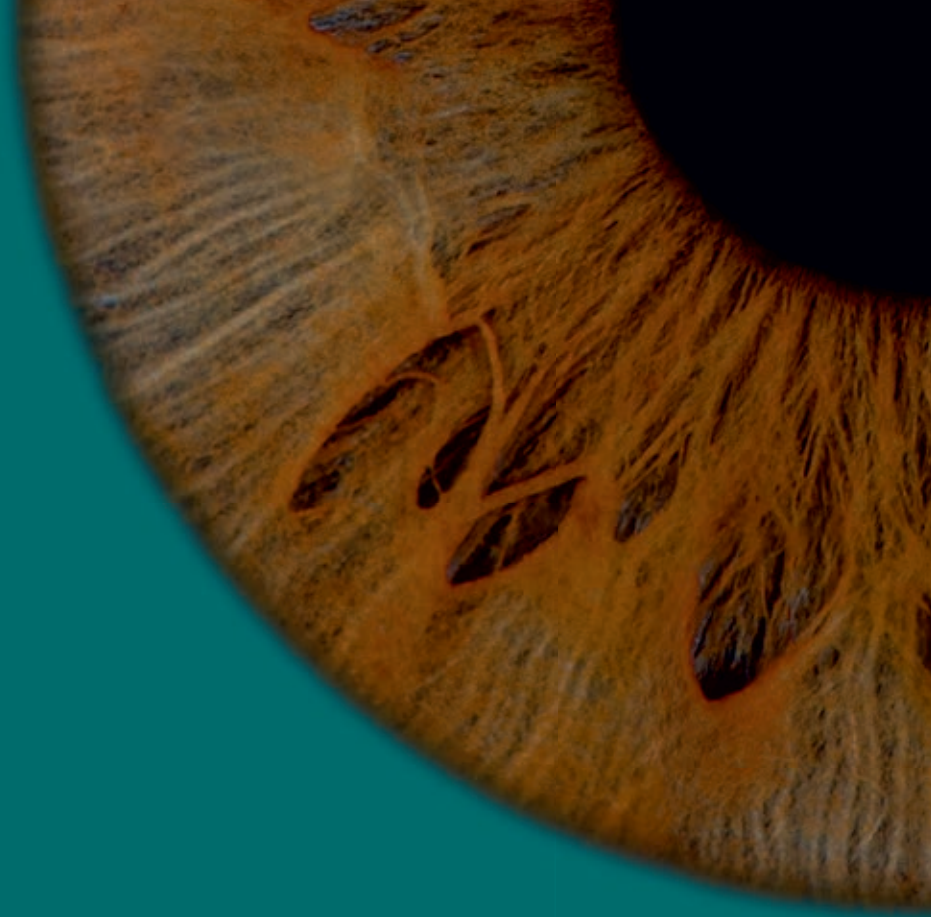
## References

1. Alinasab B, Ryott M, Stjarne P: Still no reliable consensus in management of blow-out fracture. *Injury* 45: 197-202, 2014
2. Dubois L, Steenen SA, Gooris PJJ, et al.: Controversies in orbital reconstruction - I. Defect-driven orbital reconstruction: a systematic review. *Int J Oral Maxillofac Surg* 44: 308-315, 2015
3. Dubois L, Steenen SA, Gooris PJJ, et al.: Controversies in orbital reconstruction - II. Timing of post-traumatic orbital reconstruction: a systematic review. *Int J Oral Maxillofac Surg* 44: 433-440, 2015
4. Gosau M, Schoneich M, Draenert FG, et al.: Retrospective analysis of orbital floor fractures - Complications, outcome and review of literature. *Clin Oral Invest* 15: 305-313, 2011
5. Ramieri G, Spada MC, Bianchi SD, et al.: Dimensions and volumes of the orbit and orbital fat in posttraumatic enophthalmos. *Dentomaxillofac Radiol* 29: 302-311, 2000
6. Noser H, Hammer B, Kamer L: A method for assessing 3D shape variations of fuzzy regions and its application on human bony orbits. *J Digit Imaging* 23: 422-429, 2010
7. Andrades P, Hernandez D, Falguera MI, et al.: Degrees of tolerance in post-traumatic orbital volume correction: the role of prefabricated mesh. *J Oral Maxillofac Surg* 67: 2404-2411, 2009
8. Cai EZ, Koh YP, Hing ECH, et al.: Computer-assisted navigational surgery improves outcomes in orbital reconstructive surgery. *J Craniofac Surg* 23: 1567-1573, 2012
9. Dubois L, Schreurs R, Jansen J, et al.: Predictability in orbital reconstruction: a human cadaver study. Part II: navigation-assisted orbital reconstruction. *J Craniomaxillofac Surg* 43: 2042-2049, 2015
10. Dubois L, Essig H, Schreurs R, et al.: Predictability in orbital reconstruction. A human cadaver study. Part III: implant-oriented navigation for optimized reconstruction. *J Craniomaxillofac Surg* 43: 2050-2056, 2015
11. Metzger MC, Hohlweg-Majert B, Schon R, et al.: Verification of clinical precision after computer-aided reconstruction in craniomaxillofacial surgery. *Oral Surg Oral Med Oral Pathol Oral Radiol Endod* 104: 1-10, 2007
12. Novelli G, Tonellini G, Mazzoleni F, et al.: Virtual surgery simulation in orbital wall reconstruction: integration of surgical navigation and stereolithographic models. *J Craniomaxillofac Surg* 42: 2025-2034, 2014
13. Rana M, Chui CHK, Wagner M, et al.: Increasing the accuracy of orbital reconstruction with selective laser-melted patient-specific implants combined with intraoperative navigation. *J Oral Maxillofac Surg* 73: 1113-1118, 2015
14. Schramm A, Suarez-Cunqueiro MM, Rücker M, et al.: Computer-assisted therapy in orbital and mid-facial reconstructions. *Int J Med Robot* 5: 111-124, 2009
15. Gui H, Yang H, Zhang S, et al.: Mirroring tool: the simplest computer-aided simulation technology? *J Craniofac Surg* 26: 2115-2119, 2015
16. Pierrefeu A, Terzic A, Volz A, et al.: How accurate is the treatment of midfacial fractures by a specific navigation system integrating "mirroring" computational planning? Beyond mere average difference analysis. *J Oral Maxillofac Surg* 73: 315.e1-315.e10, 2015
17. Ferrario V, Sforza C, Ciusa V, et al.: The effect of sex and age on facial asymmetry in healthy subjects: a cross-sectional study from adolescence to mid-adulthood. *J Oral Maxillofac Surg* 59: 283-288, 2001
18. Sanders DA, Chandhoke TK, Uribe FA, et al.: Quantification of skeletal asymmetries in normal adolescents: cone-beam computed tomography analysis. *Prog Orthod* 15: 26, 2014
19. Thornhill R, Gangstedt SW: Facial attractiveness. *Trends Cog Sci* 3: 452-460, 1999
20. Jansen J, Schreurs R, Dubois L, et al.: Orbital volume analysis: validation of a semi-automatic software segmentation method. *Int J Comput Assist Radiol Surg* 11: 11-18, 2016
21. Maes F, Collignon A, Vandermeulen D, et al.: Multimodality image registration by maximization of mutual information. *IEEE Trans Med Imaging* 16: 187-198, 1997

22. Almkhatar A, Ju X, Khambay B, et al.: Comparison of the accuracy of voxel-based registration and surface based registration for 3D assessment of surgical change following orthognathic surgery. *PLoS One* 9: e93402, 2014
23. Kuipers MA, Desmedt DJ, Nada RM, et al.: Regional facial asymmetries in unilateral orofacial clefts. *Eur J Orthod* 37: 636-642, 2015
24. Ercan I, Ozdemir ST, Etoz A, et al.: Facial asymmetry in young healthy subjects evaluated by statistical shape analysis. *J Anat* 213: 663-669, 2008
25. Lu KH: Harmonic analysis of the human face. *Biometrics* 21: 491-505, 1965
26. Gellrich NC, Schramm A, Hammer B, et al.: Computer-assisted secondary reconstruction of unilateral posttraumatic orbital deformity. *Plast Reconstr Surg* 110: 1417-1429, 2002
27. Koo L, Hatton MP, Rubin PA: When is enophthalmos "significant"? *Ophthal Plast Reconstr Surg* 22: 274-277, 2006
28. Zhang Z, Zhang Y, He Y, et al.: Correlation between volume of herniated orbital contents and the amount of enophthalmos in orbital floor and wall fractures. *J Oral Maxillofac Surg* 70: 68-73, 2012
29. Metzger MC, Schon R, Tetzlaff R, et al.: Topographical CT-data analysis of the human orbital floor. *Int J Oral Maxillofac Surg* 36: 45-53, 2007
30. Forbes G, Gehring DG, Gorman CA, et al.: Volume measurements of normal orbital structures by computed tomographic analysis. *AJR Am J Roentgenol* 145: 149-154, 1985
31. Felding UA, Bloch SL, von Buchwald C: The dimensions of the orbital cavity based on high-resolution computed tomography of human cadavers. *J Craniofac Surg* 27: 1090-1093, 2016
32. Alinasab B, Beckman MO, Pansell T, et al.: Relative difference in orbital volume as an indication for surgical reconstruction in isolated orbital floor fractures. *Craniofac Trauma Reconstr* 4: 203-212, 2011
33. Kamer L, Noser H, Schramm A, et al.: Orbital form analysis: problems with design and positioning of precontoured orbital implants. A serial study using post-processed clinical CT data in unaffected orbits. *Int J Oral Maxillofac Surg* 39: 666-672, 2010
34. Kamer L, Noser H, Schramm A, et al.: Anatomy-based surgical concepts for individual orbital decompression surgery in Graves orbitopathy. I. Orbital size and geometry. *Ophthal Plast Reconstr Surg* 26: 348-352, 2010
35. Damstra J, Fourie Z, De Wit M, et al.: A three-dimensional comparison of a morphometric and conventional cephalometric midsagittal planes for craniofacial asymmetry. *Clin Oral Investig* 16: 285-294, 2012
36. Gateno J, Jajoo A, Nicol M, et al.: The primal sagittal plane of the head: a new concept. *Int J Oral Maxillofac Surg* 45: 399-405, 2016
37. Burnstine MA: Clinical recommendations for repair of isolated orbital floor fractures: an evidence-based analysis. *Ophthalmology* 109: 1207-1213, 2002
38. Clauser L, Galiè M, Pagliaro F, et al.: Posttraumatic enophthalmos: etiology, principles of reconstruction, and correction. *J Craniofac Surg* 19: 351-359, 2008







# CHAPTER 4

## Computer-assisted preoperative planning to improve implant position in orbital reconstruction

This chapter is based on the publication:  
*The advantages of advanced computer-assisted diagnostics and three-dimensional preoperative planning on implant position in orbital reconstruction*

*J. Jansen, R. Schreurs, L. Dubois, T.J.J. Maal, P.J.J. Gooris, A.G. Becking*

*Published in:  
Journal of Cranio-Maxillofacial Surgery, 2018*

## Abstract

**Purpose:** Advanced three-dimensional (3D) diagnostics and preoperative planning are the first steps in computer-assisted surgery (CAS). They are an integral part of the workflow, and allow the surgeon to adequately assess the fracture and to perform virtual surgery to find the optimal implant position. The goal of this study was to evaluate the accuracy and predictability of 3D diagnostics and preoperative virtual planning without intraoperative navigation in orbital reconstruction.

**Materials and methods:** In ten cadaveric heads, 19 complex orbital fractures were created. First, all fractures were reconstructed without preoperative planning (control group) and at a later stage the reconstructions were repeated with the help of preoperative planning. Prefabricated titanium mesh plates were used for the reconstructions by two experienced oral and maxillofacial surgeons. The preoperative virtual planning was easily accessible for the surgeon during the reconstruction. Computed tomography scans were obtained before and after creation of the orbital fractures and postoperatively. Using a paired *t* test, implant positioning accuracy (translation and rotations) of both groups were evaluated by comparing the planned implant position with the position of the implant on the postoperative scan.

**Results:** Implant position improved significantly ( $p < 0.05$ ) for translation, yaw, and roll in the group with preoperative planning (Table 1). Pitch did not improve significantly ( $p = 0.78$ ).

**Conclusion:** The use of 3D diagnostics and preoperative planning without navigation in complex orbital wall fractures has a positive effect on implant position. This is due to a better assessment of the fracture, the possibility of virtual surgery and because the planning can be used as a virtual guide intraoperatively. The surgeon has more control in positioning the implant in relation to the rim and other bony landmarks.

## Introduction

Innovative surgical devices and diagnostic equipment for orbital wall fractures, such as surgical navigation or endoscopy, are extensively used in clinical practice<sup>1-5</sup>. The success rates of these modalities vary, yet they all aim at improving the visualisation of the fracture and the predictability of implant placement<sup>6-8</sup>. Combined fractures of the orbital floor and medial wall in particular present a reconstructive challenge due to the anatomy of the orbit. Postoperative complications occur due to suboptimal orbital reconstruction<sup>9-11</sup>. Preoperative virtual planning, as part of computer-assisted surgery (CAS), is thought to be a valuable addition on its own in achieving a pretraumatic anatomical reconstruction.

The focus of CAS is on improving accuracy, usability, and possible shortening of operation time<sup>8,12,13</sup>. It is used for several purposes, ranging from trauma treatment to orthognathic surgery and pathological resections<sup>14-16</sup>. CAS can be divided into four steps: 1. advanced diagnostics, 2. preoperative virtual planning (including designing patient-specific implants), 3. intraoperative navigation, and 4. intraoperative and postoperative evaluation. Due to the cost, availability, and technical support, the complete workflow of CAS is limited to well-equipped centres and primarily used for complex cases. Since software becomes more easily available, the first two steps become more accessible and relatively affordable for smaller clinics.

In the current literature on CAS, the focus is on the outcome of the complete process<sup>17-19</sup>. The outcome is the sum of the contributions of all four steps. The question remains as to which steps are more crucial and contribute most to the outcome. If the advanced diagnostics and virtual planning steps are crucial in increasing accuracy and reliability, then the more time-consuming, expensive, and technical step of navigation-assisted surgery may be discarded in some cases.

The aim of this study was to measure the additional value of three-dimensional preoperative virtual diagnostics and planning and evaluate the effects on implant position in orbital floor and medial wall fractures. To our knowledge, the preoperative steps (advanced diagnostics and

virtual planning) have never been separately assessed in CAS studies. Our hypothesis was that preoperative virtual planning, without intraoperative navigation, improves the position of the implant and may even be the most important step in the process of CAS.

## Materials and methods

### Materials

This cadaveric cohort study was not subject to consent by the local ethics committee, and was performed in accordance with the Declaration of Helsinki. Ten preserved and labelled human cadaver heads were obtained from the Department of Anatomy, Embryology and Physiology of the Academic Medical Center (AMC) Amsterdam. To prepare each orbit for surgery, a transconjunctival approach was used to gain sufficient visibility of the orbital floor and medial wall. Large defects (Jaquiéry class III/IV) were created in the orbital floor and/or medial wall using piezoelectric surgery (Mectron, Carasco, Italy)<sup>20</sup>. Due to sinus pathology (osteoma) one of the twenty orbits had to be excluded.

Computed tomography (CT) scans were made at the beginning of the study (intact orbital cavities), after creation of the orbital fractures, and postoperatively to check the obtained implant position. CT scans were acquired by the Siemens Sensation 64 (Siemens Healthcare, Forchheim, Germany). The scans parameters were: slice collimation 20×0.6 mm, 0.75 mm slice thickness, 0.4 mm slice increment, 512×512 matrix, 120 kV, 350 mAs, pitch 0.85, FOV 30 cm, hard-tissue convolution kernel H70s, and window W1600 L400.

Preformed orbital titanium mesh plates (KLS Martin, Tuttlingen, Germany) were used for all orbital reconstructions. These plates were imported as STL files in the planning program (iPlan software version 3.0.5; BrainLAB AG, Feldkirchen, Germany) to perform the virtual reconstruction. The optimal implant position was determined by a technician and two surgeons based on the STL file of the implant, the pretraumatised scan, and the preoperative scan.

## Methods

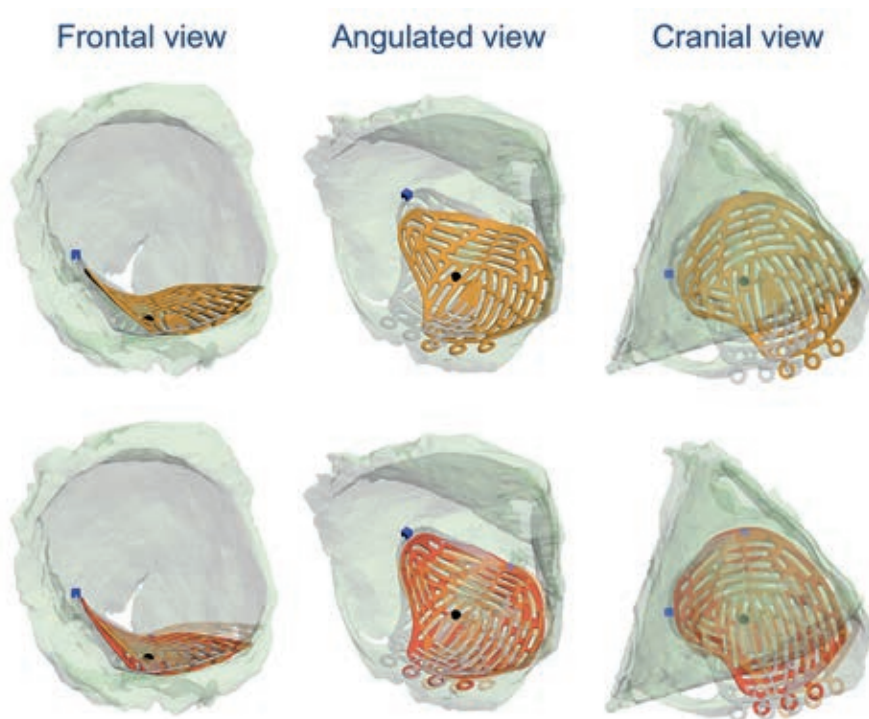
This study design was extensively introduced and discussed in earlier studies<sup>5,7,8</sup>. In the first group, one surgeon (LD) performed the reconstructions without three-dimensional (3D) virtual diagnostics and preoperative planning by using the transconjunctival approach. The surgeon was allowed to have a look at the preoperative scan. The surgeon was unaware of which cadaver he was operating on. The orbital titanium mesh plates were put in place and fixated with one bone screw in the inferior orbital rim. After completion, all cadavers were scanned, the mesh plates were removed and the drill holes were covered with DuraLay (Reliance Dental Mfg. Co, Worth, IL, USA). In the second group, the same surgeon repeated the process several months later, but now with the use of 3D diagnostics and a virtual preoperative plan of the reconstruction. The surgeon could consult the planned position of the implant as a virtual guide before and during surgery on a computer screen in the operating theatre<sup>7</sup>. To check intrasurgeon and intersurgeon repeatability for both groups, the reconstructions were repeated by two surgeons (LD and PG).

iPlan software was used to evaluate the accuracy of the implant position. The positioned implant was segmented (threshold Hounsfield units >1200) and transferred as a STL file. The Orbital Implant Positioning Frame (OIPF) superimposed the postoperative implant onto the planned preoperative implant position for every reconstruction<sup>20</sup>. The OIPF calculated differences in translation and rotations (pitch, yaw, and roll) in relation to the ideal planned position using the iterative closest point approach (Fig. 1). Translation was measured as total displacement, resulting in the Euclidean distance of the translation in the x, y, and z direction.

## Statistical analysis

Statistical data analysis was performed using SPSS Statistics (version 22.0; IBM Corp., Armonk, NY, USA). For all results the pitch, yaw, roll, and translation of the ideal planned position was compared to the postoperative actual position. This was performed for both groups (with and without preoperative planning). Intersurgeon and intrasurgeon variability was calculated for both surgeons using the intraclass correlation

coefficient (ICC). The paired  $t$  test was used to compare the absolute and relative mean and standard deviation and  $p < 0.05$  was considered statistically significant. Plots were created to visualise the spread of the implant positions.



**Figure 1** Mean deviation between postoperative implant position and ideal implant position (translucent grey). Above the postoperative position without preoperative planning (orange). Below the postoperative position with preoperative planning (red) and without preoperative planning (translucent orange).

## Results

### Intrasurgeon and intersurgeon repeatability

As shown in Table 1, the intrasurgeon repeatability in the preoperative planning group was high for translation (ICC 0.80; 95 % CI 0.33-0.95), roll (ICC 0.86; 95 % CI 0.49-0.97), and pitch (ICC 0.64; 95 % CI 0.01-0.90), and average for yaw (0.47; 95 % CI -0.24-0.85).



The intersurgeon repeatability in the preoperative planning group (between LD and PG) was high for pitch (ICC 0.89; CI 0.62-0.97) and yaw (ICC 0.65; CI 0.08-0.90) and low for translation (ICC 0.07; CI -0.56-0.65) and roll (ICC 0.39; CI -0.28-0.80).

**Table 1** Intersurgeon and intrasurgeon repeatability (ICC + 95 % CI).

	Without planning		With planning	
	Intra	Inter	Intra	Inter
<b>Translation</b>	0.69 (0.11-0.92)	0.32 (-0.35-0.78)	0.80 (0.33-0.95)	0.07 (-0.56-0.65)
<b>Pitch</b>	0.25 (-0.45-0.76)	0.07 (-0.56-0.64)	0.64 (0.01-0.90)	0.89 (0.62-0.97)
<b>Yaw</b>	0.53 (-0.15-0.87)	0.39 (-0.28-0.80)	0.47 (-0.24-0.85)	0.65 (0.08-0.90)
<b>Roll</b>	0.74 (0.21-0.94)	0.60 (-0.01-0.88)	0.86 (0.49-0.97)	0.39 (-0.28-0.80)

### Preoperative planning versus no preoperative planning

The absolute implant position of the group with preoperative virtual planning showed a significant ( $p < 0.05$ ) improvement for translation (2.6 mm; SD 1.7 mm), yaw (7.2°; SD 4.4°), and roll (4.8°; SD 3.1°) compared to the group without preoperative planning (Table 2). The variation in pitch was not significant between both groups.

**Table 2** Absolute implant position with and without preoperative planning.

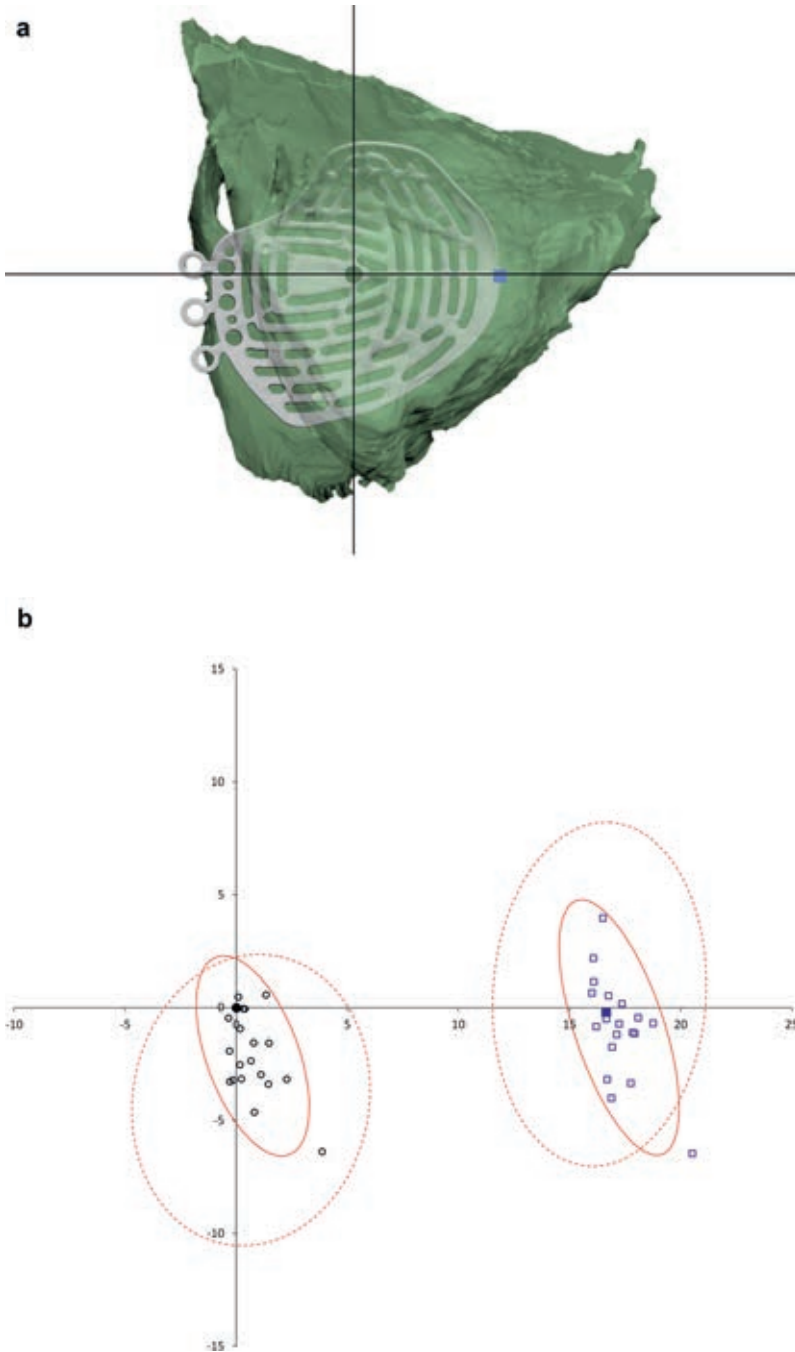
	Without planning		With planning		p value
	Mean	SD	Mean	SD	
<b>Translation</b>	5.0 mm	2.2 mm	2.6 mm	1.7 mm	<0.05
<b>Pitch</b>	2.5°	2.1°	2.0°	1.4°	0.29
<b>Yaw</b>	18.6°	9.5°	7.2°	4.4°	<0.05
<b>Roll</b>	11.1°	7.3°	4.8°	3.1°	<0.05

In Fig. 2a and Fig. 3a, the cranial and frontal view of the average implant position is illustrated including two defined points (blue square and the intersection of the two lines). In Fig. 2b and Fig. 3b, those points are illustrated in plots for all implants. The dotted and solid circles represent the 95 % confidence interval.

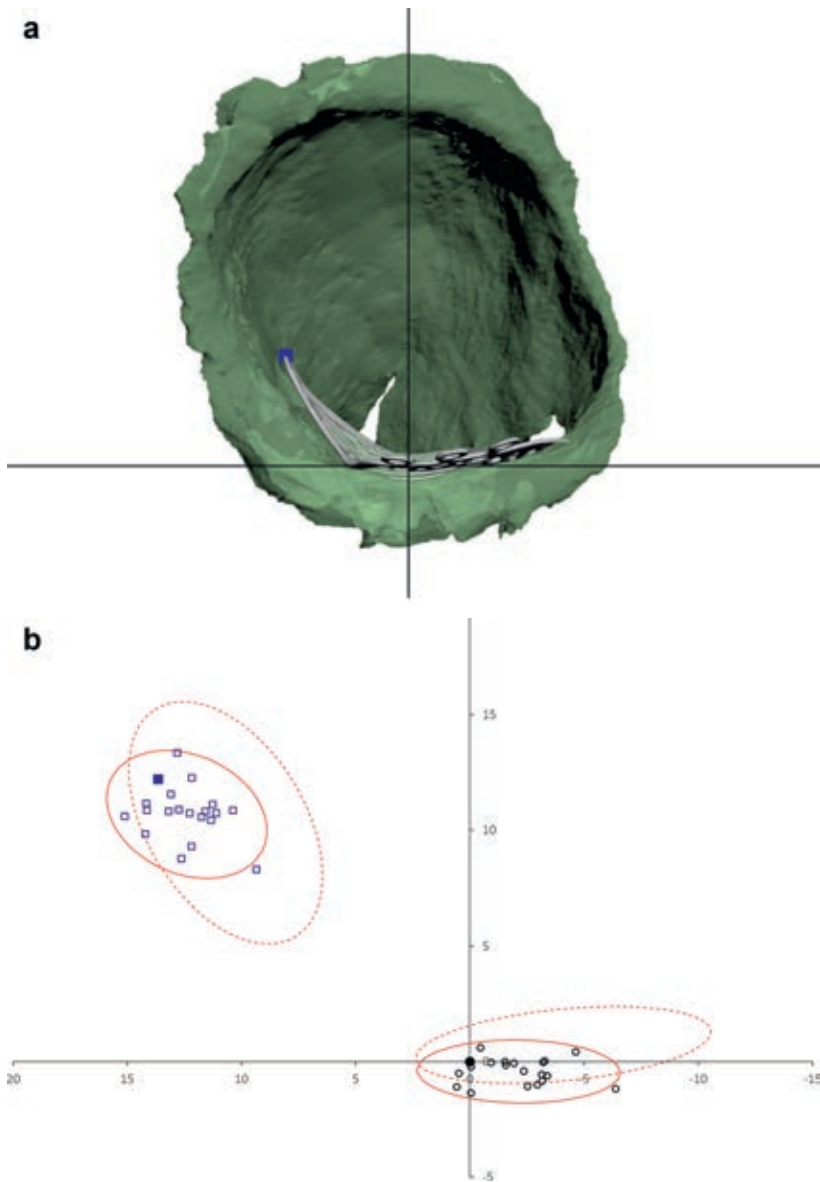
The relative mean and standard deviation of the rotations (Table 3) show that on average the final implant placement has a negative pitch and roll and a positive yaw ( $p < 0.05$ ).

**Table 3** Relative implant position of the group with preoperative planning.

	<b>Mean</b>	<b>SD</b>	<b>p value</b>
<b>Translation</b>	2.6 mm	1.7 mm	
<b>Pitch</b>	-1.1°	2.2°	<0.05
<b>Yaw</b>	5.2°	6.8°	<0.05
<b>Roll</b>	-4.5°	3.5°	<0.05



**Figure 2** (a) Cranial view of the orbital floor and average implant. (b) Plot graph in cranial view of the 95 % confidence interval of the group without planning (dotted circle) and the group with planning (solid circle).



**Figure 3** (a) Frontal view of the orbital cavity and average implant. (b) Plot graph in frontal view of the 95 % confidence interval of the group without planning (dotted circle) and the group with planning (solid circle).

## Discussion

Computer-assisted surgery (CAS) has proved to be a valuable tool in trauma surgery<sup>3,22-24</sup>. The first two steps in CAS are: 1. three-dimensional (3D) advanced diagnostics and 2. preoperative virtual planning of the orbital reconstruction. Both steps offer many possibilities. Advanced diagnostics grant the surgeon the opportunity to conduct a volumetric analysis, mirror the unaffected side, analyse the size, and extent of the fracture in comparison to several landmarks and measure angulations<sup>25</sup>. This is followed by virtual surgery to determine implant size and position and to use this as a virtual guidance during surgery. The aim of this study was to determine the importance of these steps by comparing two reconstruction groups: with and without the use of preoperative planning. The main objective was to evaluate the effect of preoperative planning without navigation on the accuracy and predictability of implant positioning.

The results demonstrate that the use of a 3D software planning tool in orbital floor and medial wall fractures improves the accuracy of implant positioning. A significant improvement in the absolute implant position is achieved for translation, roll, and yaw in comparison to the control group. The ideal implant position was compared with respect to the boundaries of the fracture, the inferior orbital rim, and the transition zone from the orbital floor to the medial wall. These additional anatomical landmarks seemed to be helpful during insertion and positioning of the implant. As shown in the results these extra landmarks are beneficial in defining the optimal position. The pitch demonstrates an improvement, but not significantly. Pitch is determined by the support of the inferior orbital rim and the posterior ledge. In most cases, these are intact, and thus there is limited variation in positioning of the implant due to the vertical support. In both groups, no implant was placed below the posterior ledge. Changes in antero-posterior placement or yaw and roll may change pitch slightly due to the curvature of the orbit. Due to these circumstances, the average difference in pitch was small for both groups, and therefore it was likely that the improvement would not be significant.



The plots in Fig. 2 and Fig. 3 illustrate the spread of the implant positions with the 95 % confidence interval in both groups. For all four indicated points, the solid circles are smaller and more centred around the average. This implies that the relative spread of the implant position is smaller in the group with preoperative planning. Mean pitch and roll are negative, and yaw is positive. This might be due to the anatomy of the orbit and pressure of the soft tissue during placement forcing the implant into a certain position. Intrasurgeon repeatability is high for translation, pitch, and roll and average for yaw. Intersurgeon repeatability is high for pitch and yaw and low for translation and roll. This may be explained by the fact that the relative deviation of the implant position is small.

Apart from the improved accuracy of the implant position, the use of virtual planning software on its own holds several other benefits. The software provides diagnostic tools (volumetric analysis, mirroring) and an in-depth overview of the anatomy, its landmarks and the actual defect to prepare for the surgery. The surgeon gains experience due to the virtual reconstruction and the fitting of different implant shapes and sizes. The planning also sets an objective target which enables the surgeon to do a postoperative analysis of the reconstruction. All these benefits make preoperative virtual planning suitable for both educational and research purposes. In severe cases, software tools such as mirroring produce a clear insight in the complexity of the case and it facilitates designing patient-specific implants<sup>14,26</sup>. It is also believed that it may act as an additional tool in decision-making towards the choice for referral to a specialised, tertiary centre. Preoperative planning software on its own is more affordable and easier to implement in less equipped clinics. If predictability and reliability improve with preoperative virtual planning, then navigation-assisted surgery may not always be necessary. Without navigation, additional expensive hardware is unnecessary, no specific scan protocol with navigation markers is needed, and no skull-fixed navigation receiver needs to be positioned. However, intraoperative control will be lacking without navigation. Postoperative or, rather, intraoperative 3D C-bow imaging will then be the most important evaluation tool for assessing reconstruction quality<sup>27,28</sup>. The combination of preoperative planning and intraoperative imaging allows the surgeon to fuse the

preoperative planned implant position with the intraoperative actual position in the operating theatre, to compare them and to directly make changes if necessary.

When comparing this study to an earlier cadaver study on navigation by the same research group, similar comparable results in accuracy of the implant positioning are published<sup>7</sup>. The reproducibility is better in the navigation study group. Possible reasons for the similar results are that by the simultaneous assessment of the operation field and the multiplanar view on the computer screen, this may distract the surgeon from the patient and the actual implant to the computer screen. If using only the planning intraoperatively, the surgeon first evaluates the ideal position and then tries to duplicate this to the actual implant position. The surgeon may also rely more on the navigation and less on its own experience. Another reason for the comparable results may be that navigation itself has small calibration and navigation errors which add up to the outcome<sup>16</sup>.

Cai et al. state that navigation minimises postoperative complications<sup>3</sup>. Their objective assessment of the actual implant position compared to the boundaries of the floor defect demonstrate an average of 3.24 mm vertical distance. To some extent this is comparable to our results. Essig et al. state that true-to-origin reconstruction was achieved in their study group<sup>18</sup>. Instead of standard preformed implants, individually bent titanium meshes were used. These results illustrate that navigation does have the potential to be extremely accurate.

The conditions of reconstruction on cadavers are different from actual surgery. Soft tissues are stiff, there is hardly any prolapse of intraocular fat and obviously no bleeding. In actual surgery, these factors are present and, in our opinion, add to the impaired visibility in the clinical situation. This would mean that preoperative virtual planning could be even more valuable in orbital reconstruction in a clinical setting than in cadavers. One of the advantages of a cadaver study is that the fractures in both groups are the same and the specimen can be assessed as often as necessary. The results in this study are based on the ideal implant position



determined by a technician and the surgeons together. A deviation from this position does not necessarily mean that it leads to impaired clinical results. For instance, volume difference and possible entrapment of soft tissue are also believed to play an important role in clinical outcome. It is impossible to include these factors in this study. A perfect bony reconstruction does not imply a perfect clinical outcome as a great variety in soft tissues changes, such as fat atrophy, tissue dislocation, and scarring due to trauma and surgery, may occur<sup>29</sup>.

Numerous computer-assisted surgery systems are available. In this study, a single software program was used, which does not automatically imply similar results for all CAS systems. In our opinion and based on the study of Strong et al. most of the systems are comparable as they rely on merely the same principles<sup>30</sup>. There were small differences in outcome, but they were considered not clinically significant. New software is increasingly available, but should be used with caution until the accuracy of the software is confirmed.

## Conclusion

The use of three-dimensional diagnostics and preoperative planning in orbital floor and medial wall fractures improves the predictability of implant positioning. They are important first steps in computer-assisted surgery, but they are also very useful on their own. Their use grants the surgeon the opportunity to analyse the size and fracture in comparison to several landmarks, to conduct volumetric analysis, and to mirror the unaffected side. Virtual surgery can be performed to determine implant size and position and can be used as a virtual guidance during surgery. Possible lack of intraoperative control can be dissolved by additionally using intraoperative navigation. Future research could focus on the combination of intraoperative imaging and preoperative planning.

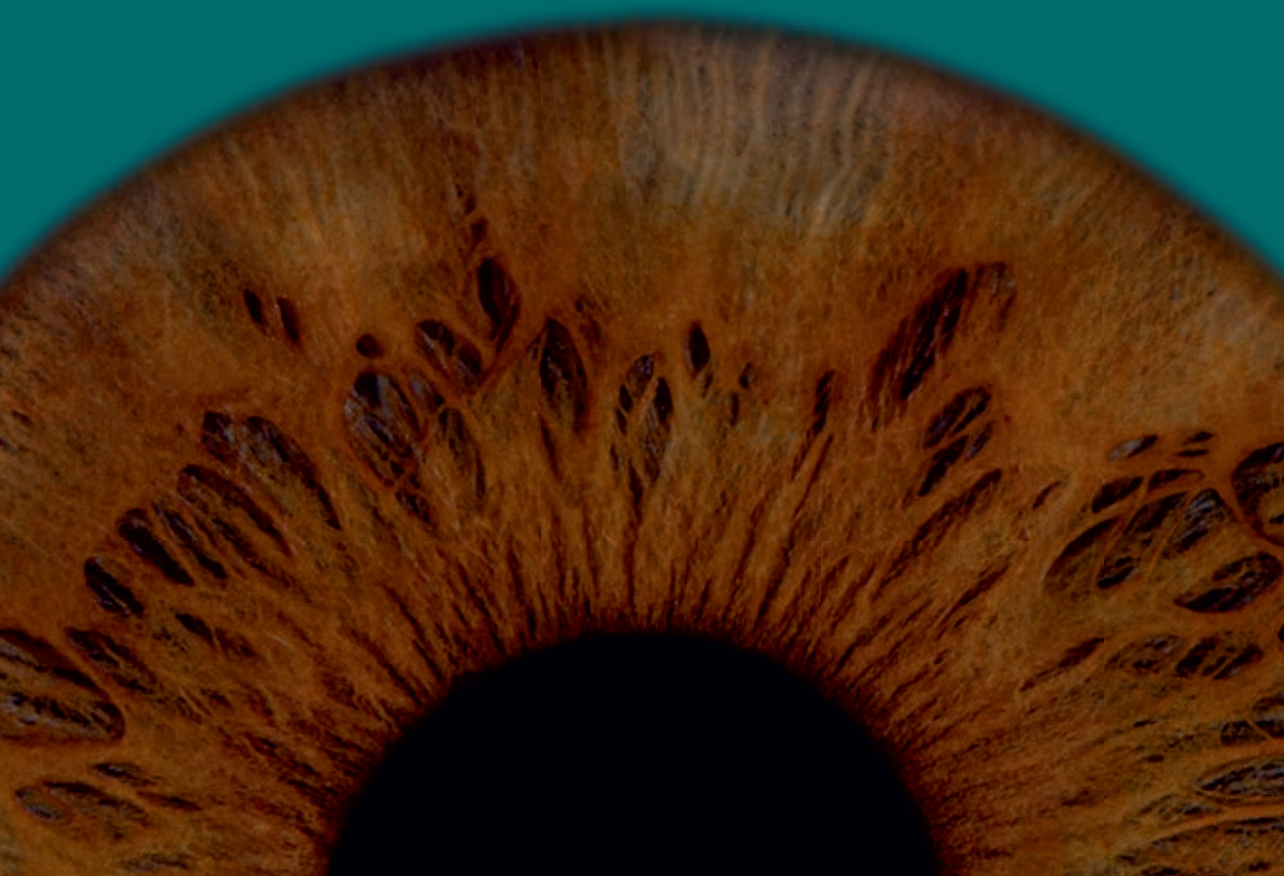

## References

1. Gellrich NC, Schramm A, Hammer B, et al.: Computer--assisted secondary reconstruction of unilateral posttraumatic orbital deformity. *Plast Reconstr Surg* 110: 1417-1429, 2002
2. Markiewicz MR, Dierks EJ, Bell RB: Does intraoperative navigation restore orbital dimensions in traumatic and post-ablative defects? *J Craniomaxillofac Surg* 40: 142-148, 2012
3. Cai EZ, Koh YP, Hing ECH, et al.: Computer-assisted navigational surgery improves outcomes in orbital reconstructive surgery. *J Craniofac Surg* 23: 1567-1573, 2012
4. Bly RA, Chang SH, Cudejkova M, et al.: Computer-guided orbital reconstruction to improve outcomes. *JAMA Facial Plast Surg* 15: 113-120, 2013
5. Dubois L, Jansen J, Schreurs R, et al.: Predictability in orbital reconstruction: a human cadaver study. Part I: endoscopic-assisted orbital reconstruction. *J Craniomaxillofac Surg* 43: 2034-2041, 2015
6. Schmelzeisen R, Gellrich NC, Schoen R, et al.: Navigation-aided reconstruction of medial orbital wall and floor contour in cranio-maxillofacial reconstruction. *Injury* 35: 955-962, 2004
7. Dubois L, Schreurs R, Jansen J, et al.: Predictability in orbital reconstruction: a human cadaver study. Part II: navigation-assisted orbital reconstruction. *J Craniomaxillofac Surg* 43: 2042-2049, 2015
8. Dubois L, Essig H, Schreurs R, et al.: Predictability in orbital reconstruction. A human cadaver study. Part III: implant-oriented navigation for optimized reconstruction. *J Craniomaxillofac Surg* 43: 2050-2056, 2015
9. Brucoli M, Arcuri F, Cavenaghi R, et al.: Analysis of complications after surgical repair of orbital fractures. *J Craniofac Surg* 22: 1387-1390, 2011
10. Jung H, Byun JY, Kim HJ, et al.: Prognostic CT findings of diplopia after surgical repair of pure orbital blowout fracture. *J Craniomaxillofac Surg* 44: 1479-1484, 2016
11. Liu SR, Song XF, Li ZK, et al.: Postoperative improvement of diplopia and extraocular muscle movement in patients with reconstructive surgeries for orbital floor fractures. *J Craniofac Surg* 27: 2043-2049, 2016
12. Hassfeld S, Mühling J, Zöller J: Intraoperative navigation in oral and maxillofacial surgery. *Int J Oral Maxillofac Surg* 24: 111-119, 1995
13. Siessegger M, Mischkowski RA, Schneider BT, et al.: Image guided surgical navigation for removal of foreign bodies in the head and neck. *J Craniomaxillofac Surg* 29: 321-325, 2001
14. Rana M, Chui CH, Wagner M, et al.: Increasing the accuracy of orbital reconstruction with selective laser-melted patient-specific implants combined with intraoperative navigation. *J Oral Maxillofac Surg* 73: 1113-1118, 2015
15. Benateau H, Chatellier A, Caillot A, et al.: Computer-assisted planning of distraction osteogenesis for lower face reconstruction in gunshot traumas. *J Craniomaxillofac Surg* 44: 1583-1591, 2016
16. Azarmehr I, Stokbro K, Bell B, et al.: Surgical navigation: a systematic review of indications, treatments, and outcomes in oral and maxillofacial surgery. *J Oral Maxillofac Surg* 75: 1987-2005, 2017
17. Metzger MC, Hohlweg-Majert B, Schon R, et al.: Verification of clinical precision after computer-aided reconstruction in craniomaxillofacial surgery. *Oral Surg Oral Med Oral Pathol Oral Radiol Endod* 104: 1-10, 2007
18. Essig H, Dressel L, Rana M, et al.: Precision of posttraumatic primary orbital reconstruction using individually bent titanium mesh with and without navigation: a retrospective study. *Head Face Med* 9: 18, 2013
19. Shin HS, Kim SY, Cha HG, et al.: Real time navigation-assisted orbital wall reconstruction in blowout fractures. *J Craniofac Surg* 27: 370-373, 2016
20. Jaquiéry C, Aeppli C, Cornelius P, et al.: Reconstruction of orbital wall defects: critical review of 72 patients. *Int J Oral Maxillofac Surg* 36: 193-199, 2007

21. Schreurs R, Dubois L, Becking AG, et al.: Quantitative assessment of orbital implant position - A proof of concept. *PLoS ONE* 11: e0150162, 2016
22. Zhang S, Gui H, Lin Y, et al.: Navigation-guided correction of midfacial post-traumatic deformities (Shanghai experience with 40 cases). *J Oral Maxillofac Surg* 70: 1426-1433, 2012
23. Yu H, Shen SG, Wang X, et al.: The indication and application of computer-assisted navigation in oral and maxillofacial surgery - Shanghai's experience based on 104 cases. *J Craniomaxillofac Surg* 41: 770-774, 2013
24. Novelli G, Tonellini G, Mazzoleni F, et al.: Virtual surgery simulation in orbital wall reconstruction: integration of surgical navigation and stereolithographic models. *J Craniomaxillofac Surg* 42: 2025-2034, 2014
25. Jansen J, Schreurs R, Dubois L, et al.: Orbital volume analysis: validation of a semi-automatic software segmentation method. *Int J Comput Assist Radiol Surg* 11: 11-18, 2016
26. Gander T, Essig H, Metzler P, et al.: Patient specific implants (PSI) in reconstruction of orbital floor and wall fractures. *J Craniomaxillofacial Surg* 43: 126-130, 2014
27. Stuck BA, Hülse R, Barth TJ: Intraoperative cone beam computed tomography in the management of facial fractures. *Int J Oral Maxillofac Surg* 41: 1171-1175, 2012
28. Blumer M, Gander T, Gujer AK, et al.: Influence of mirrored computed tomograms on decision-making for revising surgically treated orbital floor fractures. *J Oral Maxillofac Surg* 73: 1982.e1-e9, 2015
29. Clauser L, Galiè M, Pagliaro F, et al.: Posttraumatic enophthalmos: etiology, principles of reconstruction, and correction. *J Craniofac Surg* 19: 351-359, 2008
30. Strong EB, Raffi A, Holhweg-Majert B, et al.: Comparison of 3 optical navigation systems for computer-aided maxillofacial surgery. *Arch Otolaryngol Head Neck Surg* 134: 1080-1084, 2008





C  
H  
A  
P  
T  
E  
R

# 5

## Improved implant position using intraoperative imaging in orbital reconstruction

This chapter is based on the publication:  
*Intraoperative imaging in orbital reconstruction: how does it affect implant  
position?*

*J. Jansen, R. Schreurs, L. Dubois, T.J.J. Maal, P.J.J. Gooris, A.G. Becking*

*Published in:  
British Journal of Oral and Maxillofacial Surgery, 2020*

## Abstract

**Purpose:** Intraoperative imaging enables the surgeon to control the position of the implant during orbital reconstruction. Although it might improve surgical outcome and avoid the need for revision surgery, it may also increase the duration of the operation and the exposure to radiation. The goal of this study was to find out whether intraoperative imaging improves the position of the implant in reconstructions of the orbital floor and medial wall.

**Materials and methods:** Two surgeons reconstructed complex orbital fractures in ten cadavers. After the reconstruction a computed tomography scan was made to confirm the position of the implant and, if required, to make any adjustments. Scans were repeated until the surgeon was satisfied. The ideal position was ascertained by scans that were obtained before and after creation of the fractures. The position of the implant achieved was compared with that of the ideal position.

**Results:** The implant position improved significantly for yaw ( $p=0.04$ ) and roll ( $p=0.03$ ). A mean of 1.6 scans was required per reconstruction (maximum  $n=3$ ). The main reason for alteration was the rotation roll.

**Conclusion:** Intraoperative imaging significantly improves the position of the implant fractures of the orbital floor and medial wall. The surgeon has quality control of its position during the reconstruction to restore the anatomical boundaries.

## Introduction

Acquiring feedback about the position of the implant is important during reconstruction of the orbital wall<sup>1,2</sup>. In orbital surgery the overview of the fracture and position of the implant are limited by herniation of orbital fat and minimally invasive surgery<sup>3,4</sup>. Because of the complexity of the surgery a relatively high percentage of the reconstructions result in the implant being in an unfavourable position, or even needing revision surgery<sup>5</sup>. Suboptimal positioning often leads to deviations in translation and rotations, which might cause a serious increase in orbital volume and related complications such as enophthalmos<sup>6-8</sup>. Intraoperative imaging can be used to achieve an optimal position in these reconstructions<sup>9</sup>, yet it is doubtful if subtle deviations in the planned position compared with the achieved position can be assessed accurately on intraoperative computed tomography (CT) imaging without the use of three-dimensional advanced diagnostics, planning, or navigation, or all three combined.

Apart from training, experience, and preoperative planning, the surgeon could additionally rely on several methods of intraoperative evaluation such as endoscopy and surgical navigation<sup>10-12</sup>. Although navigation improves the position of the implant, it still has a certain degree of inaccuracy and revision surgery could still be necessary, even with the use of expensive navigation equipment<sup>5,13</sup>. CT scans are therefore necessary to verify the position of the implant<sup>9</sup>. The major advantages of verification of the position during surgery are direct quality control and the ability to adjust a suboptimal position.

The usability and image quality of intraoperative CT scans have improved considerably. The use of mobile scanners limits extra operating time to about 15 minutes and cone beam (CB)CT scanners (40-80  $\mu$ Sv) reduce radiation compared to the conventional CT scanner (600-800  $\mu$ Sv)<sup>14</sup>. Several studies have confirmed the effectiveness of intraoperative imaging in the reconstruction of facial fractures, such as zygomatic fractures and extensive orbital fractures<sup>15,16</sup>. The multiplanar view of the intraoperative CBCT scan seems to be sufficient for diagnosing orbital fractures and possibly for the evaluation of the position of the implant

during operation<sup>17</sup>. Furthermore, the postoperative scan becomes obsolete because of the high image quality.

The purpose of this study was to assess the effect of intraoperative imaging on the accuracy of positioning of the implant in reconstructions of the orbital wall. The question is whether the possible advantages outweigh the disadvantages, such as radiation exposure, extra operating time, and costs. It is hypothesised, based on the results of earlier studies, that large deviations in position of the implant (such as placement below the posterior ledge or close to the optic nerve) may be noticed, but minor deviations in translation and rotation are difficult to observe and adjust<sup>18</sup>.

The aims of the study were threefold: first, is there a noticeable improvement in the position of the implant after intraoperative CT? Secondly, is the surgeon able to assess the deviation in position compared with that of the planned position? Thirdly, how many scans are needed before a satisfactory position has been reached?

## Materials and methods

### Materials

This cohort study was the last of a series of studies on orbital reconstruction<sup>13,19-21</sup>. The study was not subject to consent by the local ethics committee and was done in accordance with the directions of the Declaration of Helsinki. The Department of Anatomy, Embryology and Physiology of the Amsterdam UMC (location AMC) Amsterdam provided ten preserved and labelled human cadaver heads. Prior to the study, large defects (Jaquiéry class III/IV) were created in the orbital floor or medial wall (or both) of each orbit using piezoelectric surgery (Mectron, Carasco, Italy)<sup>22</sup>. Access was gained through a transconjunctival approach to achieve adequate visibility. Only 19 orbits could be used because there was an osteoma of the maxillary sinus in one of them.

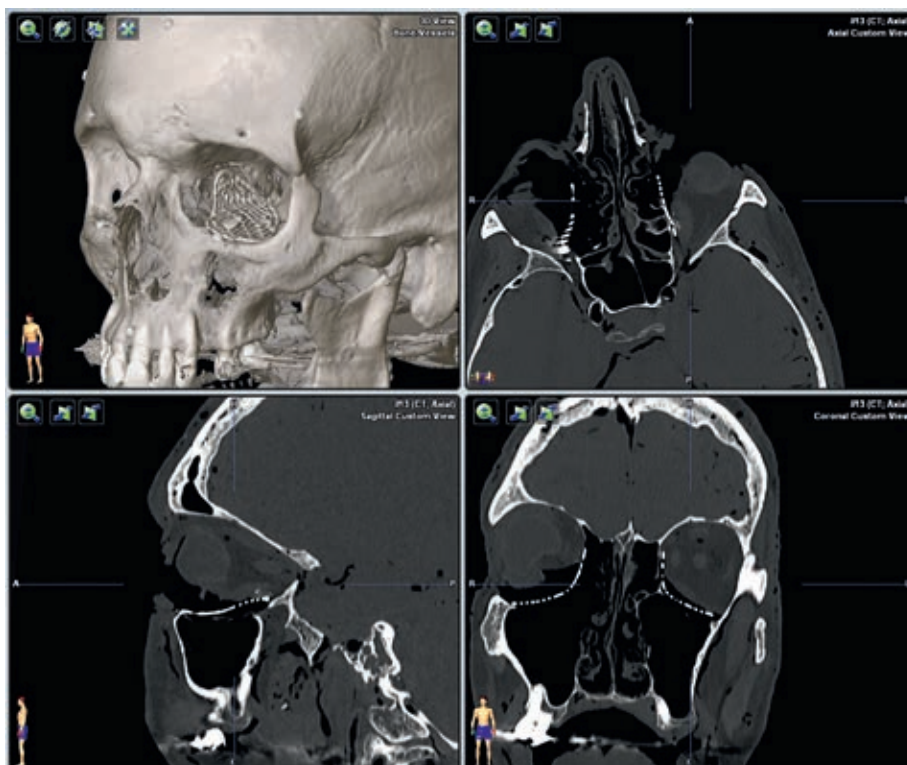
Preformed orbital titanium mesh implants (KLS Martin, Tuttlingen, Germany) were used for the reconstructions. All CT scans were acquired



by a Siemens Sensation 64 CT scanner (Siemens Healthcare, Forchheim, Germany). The scanning variables were: slice collimation 20x0.6 mm, 0.75 mm slice thickness, 0.4 mm slice increment, 512x512 matrix, 120 kV, 350 mAs, pitch 0.85, FOV 30 cm, hard tissue convolution kernel H70s and window W1600 L400.

## Methods

All reconstructions were done in the dissecting room and circumstances of an operating theatre were mimicked accurately. On day one, surgeon LD did all the reconstructions. The orbital titanium mesh plate was positioned and fixated with one bone screw in the inferior orbital rim for each fracture. After the reconstruction the cadaver was scanned and the CT scan presented in the dissecting room in multiplanar reconstruction (Fig. 1). If the surgeon was satisfied with the reconstruction, and the implant had restored the anatomical boundaries, the operation was completed. If the surgeon was unsatisfied, the position of the implant was altered and another scan taken. This was repeated until the surgeon was satisfied with the final position. After completion, all titanium implants were removed from the cadaver heads and the drill holes were covered with DuraLay (Reliance Dental Mfg. Co, Worth, Illinois, US).



**Figure 1** Multiplanar reconstruction of the intraoperative computed tomography scan.

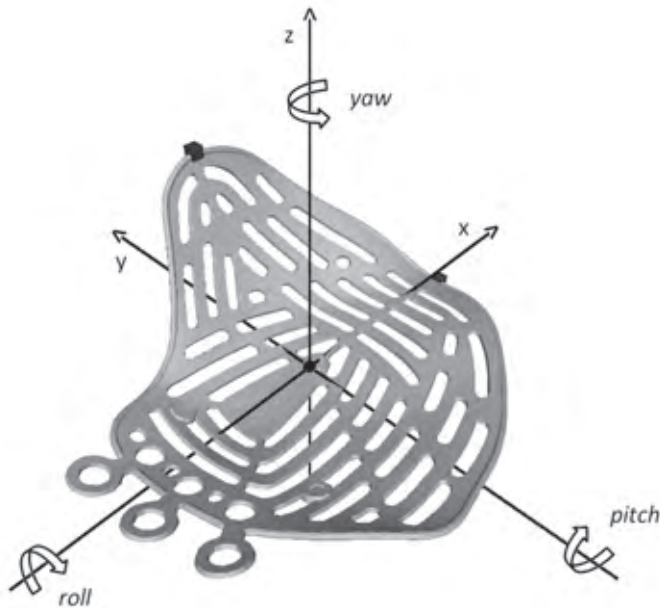
On day two, surgeon PG repeated the reconstructions using the same methods previously described to study intersurgeon repeatability. On day three, surgeon LD repeated the reconstructions to study intrasurgeon repeatability. The cadavers were disguised to prevent the surgeon from recognising the fractures.

### **Analysis of implant position**

The digital imaging and communication in medicine (DICOM) data were assessed after the completion of all reconstructions. The positions of the implants during and after surgery were compared to the ideal position. To find out the ideal position, CT scans were made before the study and after creation of the orbital fractures. These preoperative scans and the stereolithographic (STL) file of the left and right titanium implant were imported in the planning program (iPlan version 3.0.5; BrainLAB AG,

Feldkirchen, Germany) to make a virtual reconstruction. The optimal position for the implant was calculated by a technician and two surgeons based on the STL file and both preoperative scans.

As described in earlier studies, the accuracy of the positioned implant was calculated by the Orbital Implant Positioning Frame (OIPF)<sup>23</sup>. The positioned implant was superimposed onto the planned implant and differences in translation and rotations (pitch, yaw, and roll) were calculated (Fig. 2).



**Figure 2** Rotations of the implant: pitch, yaw, and roll.

### Statistical analysis

We used IBM SPSS Statistics (version 25.0; IBM Corp., Armonk, NY, USA) for statistical analysis. Descriptive statistics were used for the number of scans and the reason for altering the position of the implant. For all implants the mean (standard deviation) difference of pitch, yaw, roll, and translation of the ideal position were compared with the intraoperative position. Intersurgeon and intrasurgeon variability were calculated using the intraclass correlation coefficient (ICC). The paired *t* test was used

to compare the first position with the last position. The independent samples *t* test was used to compare all first positions. Probabilities of  $p < 0.05$  were considered significant.

## Results

### Intrasurgeon and intersurgeon repeatability

The intrasurgeon and intersurgeon repeatability are shown in Table 1, the improvement in the position of the implants in Table 2, and the satisfactory compared with unsatisfactory position of the implants in Table 3.

### Number of CT scans until satisfied

A mean of 1.6 CT scans was necessary until the surgeon was satisfied with the reconstruction and the maximum for one reconstruction was three. In half of the reconstructions the surgeon was satisfied with the implant position after the first attempt, and in the other half the alterations to the implant position were made based on the CT scan. In just under half of the cases a second or third CT scan was required.

**Table 1** Intersurgeon and intrasurgeon repeatability (ICC + 95 % CI).

	Intraoperative imaging	
	Intrasurgeon	Intersurgeon
<b>Translation</b>	0.88 (0.57-0.97)	0.74 (0.44-0.89)
<b>Pitch</b>	0.77 (0.27-0.94)	0.78 (0.51-0.91)
<b>Yaw</b>	0.64 (0.01-0.90)	0.56 (0.16-0.81)
<b>Roll</b>	0.68 (0.08-0.92)	0.34 (-0.13-0.68)

**Table 2** First scanned position compared with last scanned position.

	First		Last		p value
	Mean	SD	Mean	SD	
<b>Translation</b>	3.61 mm	1.36 mm	2.91 mm	1.02 mm	0.16
<b>Pitch</b>	2.52°	1.64°	3.74°	2.91°	0.20
<b>Yaw</b>	12.38°	10.98°	8.20°	7.85°	0.04
<b>Roll</b>	6.93°	4.25°	3.05°	2.22°	0.03

**Table 3** Satisfied with the position compared with unsatisfied with the position.

	Unsatisfied		Satisfied		p value
	Mean	SD	Mean	SD	
<b>Translation</b>	3.59 mm	1.63 mm	3.02 mm	1.35 mm	0.12
<b>Pitch</b>	2.28°	1.30°	2.73°	2.24°	0.27
<b>Yaw</b>	13.02°	9.93°	7.54°	5.87°	0.01
<b>Roll</b>	7.13°	4.65°	3.49°	2.92°	0.00

### Argumentation for altering implant position

The main reason to change the position of the implant was frontal malrotation roll (n=19). The second most important reason was axial malrotation yaw (n=9) and only once was it the translation of the implant. The sagittal malrotation pitch was never a reason to change the position of the implant.

## Discussion

Intraoperative imaging improves the reconstruction of the bony walls of the orbit. It enables the surgeon to optimise the position of the implant and minimise the need for revision surgery. Current mobile computed tomography (CT) scanners are extremely useful as they have high quality images, good operating speed, and they expose the patient to limited radiation<sup>14</sup>. The purpose of this study was to examine the effect of intraoperative imaging on the position of the implant fractures of the orbital floor and medial wall.

Intrasurgeon and intersurgeon repeatability were high for translation and pitch, indicating that the reproducibility in the use of intraoperative imaging is good. Yaw and roll were moderately high for the intraobserver repeatability and lower for the interobserver repeatability.

When comparing the implant's first position with the final position, yaw and roll improved significantly. Translation and pitch did not. These results illustrate that the surgeon is able to see that the placement of the implant is not optimal, and is also able to adjust it accordingly. Pitch did not improve significantly, as none of the implants were positioned

below the ledge, which makes the error in deviation small. As far as the pitch is concerned, it is particularly important to see if the implant is not positioned too cranially at the apex or below the posterior ledge. This can be easily seen on the sagittal images. Translation is difficult to see as expected.

The position of the implants that the surgeon was satisfied with also had a significantly better yaw and roll compared with the implants with which the surgeon was not satisfied, which shows that the surgeon was able to identify when there was a deviation in the yaw or roll of the implant.

About 1.6 CT scans were required until the surgeon was satisfied (maximum  $n=3$ ). This was comparable for both surgeons. When intraoperative and postoperative scans have a comparable dose of radiation, this implies only a minimal increase in radiation for the usual reconstruction, as a postoperative scan is no longer necessary. In our opinion, the possibility of changing the position of the implant and reducing the need for revision outweighs the increase in dose of radiation.

The primary reason for adjusting an implant was usually the observed deviation in roll and yaw. This was expected because they are best assessed in multiplanar view and the results also show that they improved significantly. The degree of translation is difficult to estimate with minimal displacements and was therefore only once the reason to change the implant. The rotation pitch was never a reason, as the deviations remained limited. The implant was never placed below the posterior ledge and only in a few reconstructions slightly too far cranially.

In the retrospective case series by Borad et al., 44 % of their implants were repositioned during operation after intraoperative imaging<sup>9</sup>. This is comparable to the half in our study. Unfortunately, the authors did not calculate if there was an actual improvement in the position of the implant. Blumer et al. stated that orbital floor fractures that had been reduced anatomically incorrectly can be reliably detected using intraoperative imaging. Between 29 and 47 % of the implants would have been adjusted if intraoperative imaging had been used<sup>5</sup>. Both studies imply that when

intraoperative imaging is available, the positions of up to 50 % of the implants are altered. Schlittler et al. evaluated the position of the implant on the postoperative scans and only 45 % of the implants were in a good position with restoration of the orbital contours<sup>24</sup>. A total of 23 % were in a poor position and in 17 % revision surgery was necessary. Over 50 % of the patients might have benefited from intraoperative imaging and revision surgery could have been prevented in some patients.

In our study the CT scans were made with a fixed CT scanner instead of a mobile three-dimensional (3D) C-arm. This improved the quality of the images slightly, but we did not expect that this would have influenced the results. The 3D C-arms produce high quality images nowadays and shows sufficient detail.

A cadaveric study is not completely comparable to reality. The absence of blood and limited soft tissue prolapse improves visibility, but this is partially undone by the increased rigidity of the skin. The improved visibility is underlined by the fact that there is no implant positioned below the posterior ledge, whilst this occasionally happens in patients. The advantage of a cadaver study is that the fractures were similar for both observers.

It remains to be seen whether the significant differences in the position of the implants actually result in clinical improvement. The loss of bony orbital support does not necessarily encourage enophthalmus to develop, partly because soft tissue factors have an important role. Nevertheless, the surgeon should consider using an intraoperative scanner when reconstruction of the orbital floor or medial wall is planned. There is limited extra radiation and operating time, yet it enables the surgeon to correct large deviations and make minimal adjustments for the optimal position of the implant.

We therefore believe intraoperative imaging has the benefit of intraoperative quality control, give direct feedback to the surgeon, and could prevent revision surgery. Additionally, preoperative virtual planning together with intraoperative imaging has the advantage that the position

reached can be superimposed onto the planned position. A postoperative CT scan is no longer required to evaluate the final position of the implant.

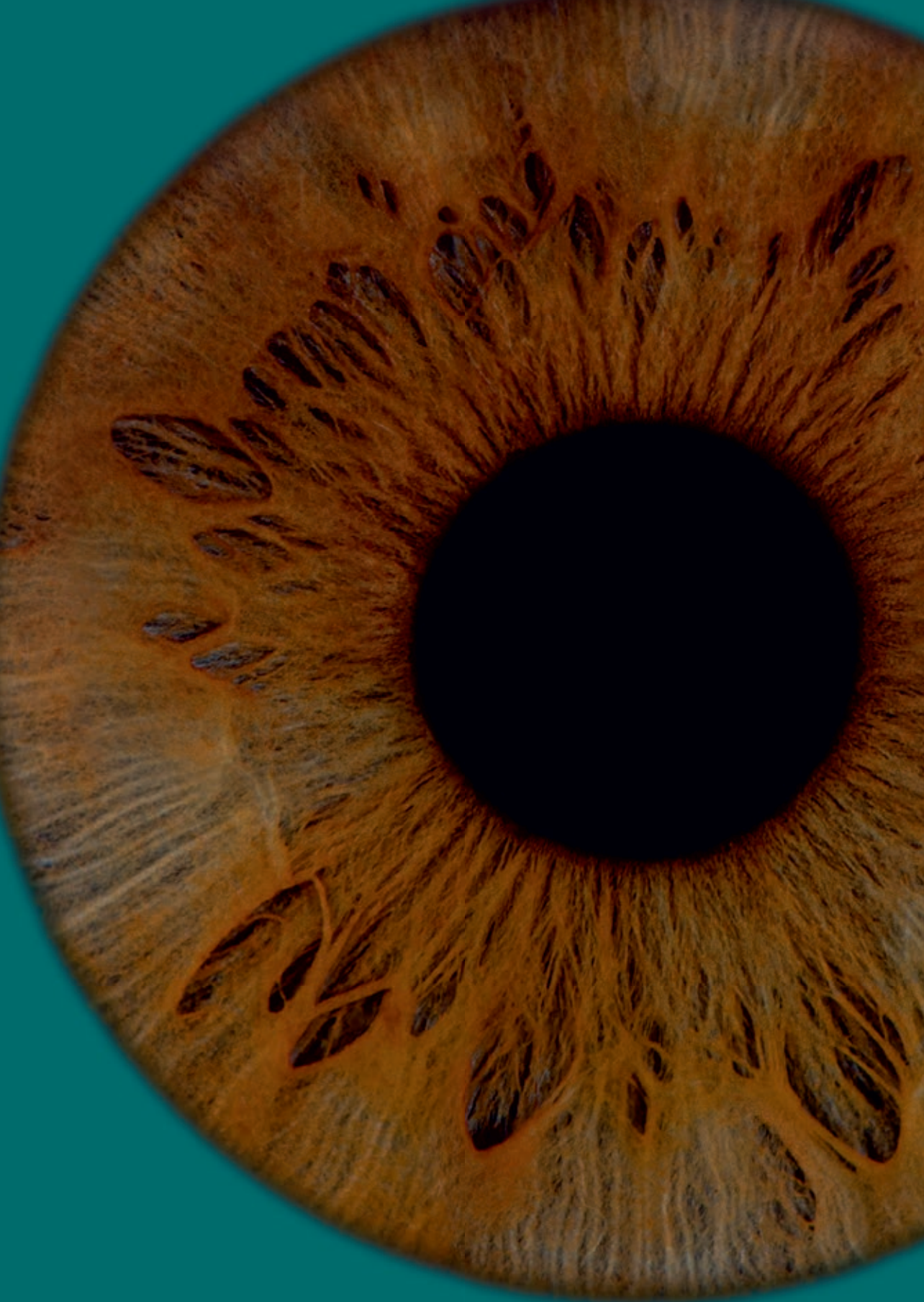## **Conclusion**

Intraoperative imaging has a significant advantageous effect on the positioning of the implant. Major deviations can be identified and may be altered to avoid revision surgery. With the current quality of the intraoperative C-arm, the radiation load and the extra operating time remain acceptable.



## References

1. Shin HS, Kim SY, Cha HG, et al.: Real time navigation-assisted orbital wall reconstruction in blowout fractures. *J Craniofac Surg* 27: 370-373, 2016
2. Azarmehr I, Stokbro K, Bell B, et al.: Surgical navigation: a systematic review of indications, treatments, and outcomes in oral and maxillofacial surgery. *J Oral Maxillofac Surg* 75: 1987-2005, 2017
3. Wilde F, Schramm A: Intraoperative imaging in orbital and midface reconstruction. *Facial Plast Surg* 30: 545-553, 2014
4. Wikner JD, Riecke B, Gröbe A, et al.: Imaging of the midfacial and orbital trauma. *Facial Plast Surg* 30: 528-536, 2014
5. Blumer M, Gander T, Gujer AK, et al.: Influence of mirrored computed tomograms on decision-making for revising surgically treated orbital floor fractures. *J Oral Maxillofac Surg* 73: 1982.e1-e9, 2015
6. Fan X, Li J, Zhu J, et al.: Computer-assisted orbital volume measurement in the surgical correction of late enophthalmos caused by blowout fractures. *Ophthal Plast Reconstr Surg* 19: 207-211, 2003
7. Clauser L, Galiè M, Pagliaro F, et al.: Posttraumatic enophthalmos: etiology, principles of reconstruction, and correction. *J Craniofac Surg* 19: 351-359, 2008
8. Brucoli M, Arcuri F, Cavenaghi R, et al.: Analysis of complications after surgical repair of orbital fractures. *J Craniofac Surg* 22: 1387-1390, 2011
9. Borad V, Lacey MS, Hamlar DD, et al.: Intraoperative imaging changes management in orbital fracture repair. *J Oral Maxillofac Surg* 75: 1932-1940, 2017
10. Cai EZ, Koh YP, Hing ECH, et al.: Computer-assisted navigational surgery improves outcomes in orbital reconstructive surgery. *J Craniofac Surg* 23: 1567-1573, 2012
11. Polligkeit J, Grimm M, Peters JP, et al.: Assessment of indications and clinical outcome for the endoscopy-assisted combined subciliary/transantral approach in treatment of complex orbital floor fractures. *J Craniomaxillofac Surg* 41: 797-802, 2013
12. Novelli G, Tonellini G, Mazzoleni F, et al.: Virtual surgery simulation in orbital wall reconstruction: Integration of surgical navigation and stereolithographic models. *J Craniomaxillofac Surg* 42: 2025-2034, 2014
13. Dubois L, Jansen J, Schreurs R, et al.: Predictability in orbital reconstruction: A human cadaver study. Part I: endoscopic-assisted orbital reconstruction. *J Craniomaxillofac Surg* 43: 2034-2041, 2015
14. Shaye DA, Tollefson TT, Strong EB: Use of intraoperative computed tomography for maxillofacial reconstructive surgery. *JAMA Facial Plast Surg* 17: 113.e1—e7, 2015
15. Stuck BA, Hülse R, Barth TJ: Intraoperative cone beam computed tomography in the management of facial fractures. *Int J Oral Maxillofac Surg* 41: 1171-1175, 2012
16. Wilde F, Lorenz K, Ebner AK, et al.: Intraoperative imaging with a 3D C-Arm system after zygomatico-orbital complex fracture reduction. *J Oral Maxillofac Surg* 71: 894-910, 2013
17. Brisco J, Fuller K, Lee N, et al.: Cone beam computed tomography for imaging orbital trauma - image quality and radiation dose compared with conventional multislice computed tomography. *Br J Oral Maxillofac Surg* 52: 76-80, 2014
18. Hoelzle F, Klein M, Schwerdtner O, et al.: Intraoperative computed tomography with the mobile CT Tomoscan M during surgical treatment of orbital fractures. *Int J Oral Maxillofac Surg* 30: 26-31, 2001
19. Dubois L, Schreurs R, Jansen J, et al.: Predictability in orbital reconstruction: a human cadaver study. Part II: navigation-assisted orbital reconstruction. *J Craniomaxillofac Surg* 43: 2042-2049, 2015
20. Dubois L, Essig H, Schreurs R, et al.: Predictability in orbital reconstruction. A human cadaver study, part III: implant-oriented navigation for optimized reconstruction. *J Craniomaxillofac Surg* 43: 2050-2056, 2015
21. Jansen J, Schreurs R, Dubois L, et al.: The advantages of advanced computer-assisted diagnostics and three-dimensional preoperative planning on implant position in orbital reconstruction. *J Craniomaxillofac Surg* 46: 715-721, 2018
22. Jaquiéry C, Aeppli C, Cornelius P, et al.: Reconstruction of orbital wall defects: critical review of 72 patients. *Int J Oral Maxillofac Surg* 36: 193-199, 2017
23. Schreurs R, Dubois L, Becking AG, et al.: Quantitative assessment of orbital implant position - A proof of concept. *PLoS ONE* 11: e0150162, 2016
24. Schlittler F, Schmidli A, Wagner F, et al.: What is the incidence of implant malpositioning and revision surgery after orbital repair? *J Oral Maxillofac Surg* 76: 146-153, 2018





P

A

R

T



Clinical perspective



C  
H  
A  
P  
T  
E  
R

# 6

## A nonsurgical approach with repeated orthoptic evaluation is justified for most blow-out fractures

This chapter is based on the publication:  
*A nonsurgical approach with repeated orthoptic evaluation is justified for most blow-out fractures*

*J. Jansen, L. Dubois, T.J.J. Maal, M.P. Mourits, H.M. Jellema, P. Neomagus,  
J. de Lange, L.J.C. Hartman, P.J.J. Gooris, A.G. Becking*

*Published in:  
Journal of Cranio-Maxillofacial Surgery, 2020*

## Abstract

**Purpose:** This study presents the results of an updated clinical protocol for orbital blow-out fractures, with a special emphasis on nonsurgical treatment and orthoptic evaluation of functional improvement.

**Materials and methods:** A two-centre multidisciplinary prospective cohort study was designed to monitor the results of a clinical protocol by assessing ductions, diplopia, globe position, and fracture size. Patients underwent clinical assessment and orthoptic evaluation at first presentation and then at 2 weeks and 3/6/12 months after nonsurgical or surgical treatment. Outcome parameters were field of binocular single vision (BSV), ductions, degree of enophthalmos, a diplopia quality-of-life (QoL) questionnaire, and other sequelae or surgical complications.

**Results:** 46 of the 58 patients that completed the 3, 6, and/or 12-month follow-up received nonsurgical treatment. There was full recovery without diplopia or enophthalmos ( $>2$  mm) in 45 of the 58 patients. The other 13 patients had limited diplopia, mainly in extreme upward gaze (average BSV 90). Five of those 13 patients did not experience impairment of diplopia in daily life. The average QoL score at the end of follow-up was 97. No patients developed late enophthalmos.

**Conclusion:** This study showed that a high percentage of patients with an orbital floor and/or medial wall fracture recovered spontaneously without lasting diplopia or cosmetically disfiguring enophthalmos. The conservative treatment protocol assessed here underlines the importance of orthoptic evaluation of functional parameters.

## Introduction

The management of blow-out fractures remains open to discussion after decades of predominantly retrospective research<sup>1-8</sup>. Some authors suggest that a defect size of  $>2 \text{ cm}^2$  or  $>50 \%$  of the surface measured on the computed tomography (CT) scan is considered an indication for surgery<sup>5,8-10</sup>. Unfortunately, the defect size is easily overestimated, which may potentially lead to overtreatment<sup>11</sup>. Moreover, measuring defect size based on CT scans is not the most effective way to predict enophthalmos<sup>12,13</sup>. Some authors argue that the herniated volume, the orbital volume ratio, or the location of the fracture, with or without involvement of the posterior ledge and inferomedial strut, are better predictors of enophthalmos<sup>14-16</sup>.

Diplopia and limited motility of the globe are also indications for surgery. In most studies this is merely a subjective observation measured shortly after trauma and not an objective, accurate, and standardised consecutive measurement performed by an orthoptist<sup>17-19</sup>. Some groups stress the importance of quantitative evaluation of ocular motility<sup>20,21</sup>. Moreover, further improvement of globe motility can occur weeks or even months after trauma<sup>22</sup>.

The ideal timing for orbital reconstruction is not well established. Some studies show that a delay in treatment does not interfere with outcome, while other studies propose a more aggressive approach<sup>23-26</sup>. Unless there are immediate indications, such as a trapdoor phenomenon with muscle entrapment or significant globe displacement, surgery is usually delayed until initial swelling has resolved. Early surgery ( $<2$  weeks) is sometimes proposed to prevent late enophthalmos or persistent diplopia. Several studies show that enophthalmos does not necessarily develop in all cases<sup>6,22</sup>. The rationale behind early surgery is that the fracture is more accessible, and less iatrogenic damage is caused due to absence of fibrosis and fewer adhesions in the soft orbital tissues<sup>27,28</sup>. However, there is insufficient proof that postponing surgery has adverse effects on outcome<sup>24,29-31</sup>.

The globe and the ocular muscles receive ligamental support from a network of connective tissue septa that are attached to the orbital walls<sup>3</sup>. The goal of orbital reconstruction is to restore the anatomical contour of the orbital walls to provide support to the orbital soft tissue, while entrapped orbital muscles and fat tissue are released and repositioned. By restoring the orbital volume, the surgeon aims for a better projection of the globe<sup>32,33</sup>.

Morbidity in orbital surgery may be severe and incapacitating. The three most common iatrogenic sequelae are enophthalmos, diplopia, and infraorbital nerve hypesthesia<sup>34</sup>. Entropion, ectropion, and visible scarring may occur as a result of surgical access<sup>35</sup>. The worst-case scenario is visual impairment and blindness following optic neuropathy, caused by pressure due to retrobulbar hemorrhage or careless surgical handling<sup>36</sup>. All these factors influence the choice in favour or against orbital reconstruction after orbital trauma.

Nonsurgical treatment relies on the regenerative capacity of the body. Periorbital soft tissue oedema, emphysema, and haematoma in general decrease gradually in the first few weeks<sup>6</sup>. The contused ocular muscles and nerves may also recuperate. All these conditions lead to temporary muscle imbalance and double vision<sup>37,38</sup>. In the long term, adaptability of the brain may reduce diplopia through a binocular fusion mechanism<sup>39</sup>. Adhesions, fibrosis, and atrophy may impair the recovery of diplopia and possibly induce enophthalmos.

The objective of this study was to monitor the outcome of an updated conservative clinical protocol for pure orbital floor and/or medial wall fractures. The aim was to produce a standardised, multidisciplinary, clinical treatment protocol.



## Materials and methods

### Study design

A two-centre, multidisciplinary, prospective, observational cohort study was designed to monitor outcome of an updated clinical research protocol. The protocol divided patients in two study groups – one receiving surgical treatment and the other nonsurgical treatment. This study was conducted in accordance with the World Medical Association Declaration of Helsinki on medical research ethics. The approval of this study was waived by the institutional medical ethical authority (file number W13\_303 # 13.17.373) and informed consent was acquired for all patients who participated in the study. All data were anonymised and de-identified prior to analysis. Consecutive patients with an orbital floor and/or medial wall fracture attending the Amsterdam UMC (location AMC) or the Amphia Hospital Breda between April 1, 2014 and April 1, 2017 were included. Inclusion criteria were patients aged 18 years or older with an isolated orbital floor and/or medial fracture that was no older than 7 days. Exclusion criteria were the presence of other orbital fractures, globe perforation, relevant pre-existing pathology of the eye (e.g. amblyopia, squint, or diplopia) or the inability to undergo the diagnostic examination.

### Study protocol

#### *First presentation*

Clinical examination was performed (subjective diplopia, enophthalmos, infraorbital hypesthesia, hypoglobus, pain, and other symptoms) and a computed tomography (CT) scan (orbital series, 1 mm slices) was obtained. Ophthalmic and orthoptic examinations (exophthalmometry, vision, bulb pressure, ductions, and field of binocular single vision (BSV)) were performed and recorded as early as possible. If there were any restrictions (e.g. obstructions due to swelling or lacerations) in performing these tests they were noted. Based on the measurements and the severity of the fracture the patient was included in either the surgical or nonsurgical group. A trapdoor fracture, persisting oculocardiac reflex, or vertical globe displacement into the maxillary sinus required immediate surgery within 24 hours. Early enophthalmos (>2 mm) or a fracture with Jaquiéry classification II/III/IV in combination with a limitation in elevation

of less than 15 degrees or abduction less than 25 degrees was an indication for early surgery (<2 weeks)<sup>40</sup>. Defect size alone, in absence of enophthalmos, was no indication for surgery. Patients were advised to perform monocular orthoptic exercises three times a day for the first week. Patients without all above-mentioned criteria were placed in the nonsurgical group (Fig. 1).

### *Nonsurgical group*

For the nonsurgical group, a control visit was scheduled within 10-14 days. Clinical, ophthalmic and orthoptic examination were repeated, including a diplopia quality-of-life (QoL) questionnaire. Patients were transferred to the surgical group if significant enophthalmos (>2 mm) had developed or ductions and diplopia showed a limited improvement. Improvement was defined as binocular single vision in primary gaze and improvement of duction of >8 degrees in the most limited position. If orthoptic examination was not performed in the first week (e.g. due to swelling), it was impossible to measure improvement. Therefore, a limitation in elevation of less than 15 degrees or abduction less than 25 degrees after 2 weeks was an indication to perform surgery. A bony reconstruction was performed within 7 days. In all other cases, the patient would remain in the nonsurgical group.

Three months ( $\pm$  7 days), 6 months ( $\pm$  14 days), and 12 months ( $\pm$  14 days) after first presentation, follow-up visits were scheduled for clinical, ophthalmologic, and orthoptic examination, and the QoL questionnaire. Limiting diplopia and ductions or enophthalmos >2 mm were late indications to transfer to the surgical group. Some rare sequelae (e.g. persistent pain) were also considered for surgery.

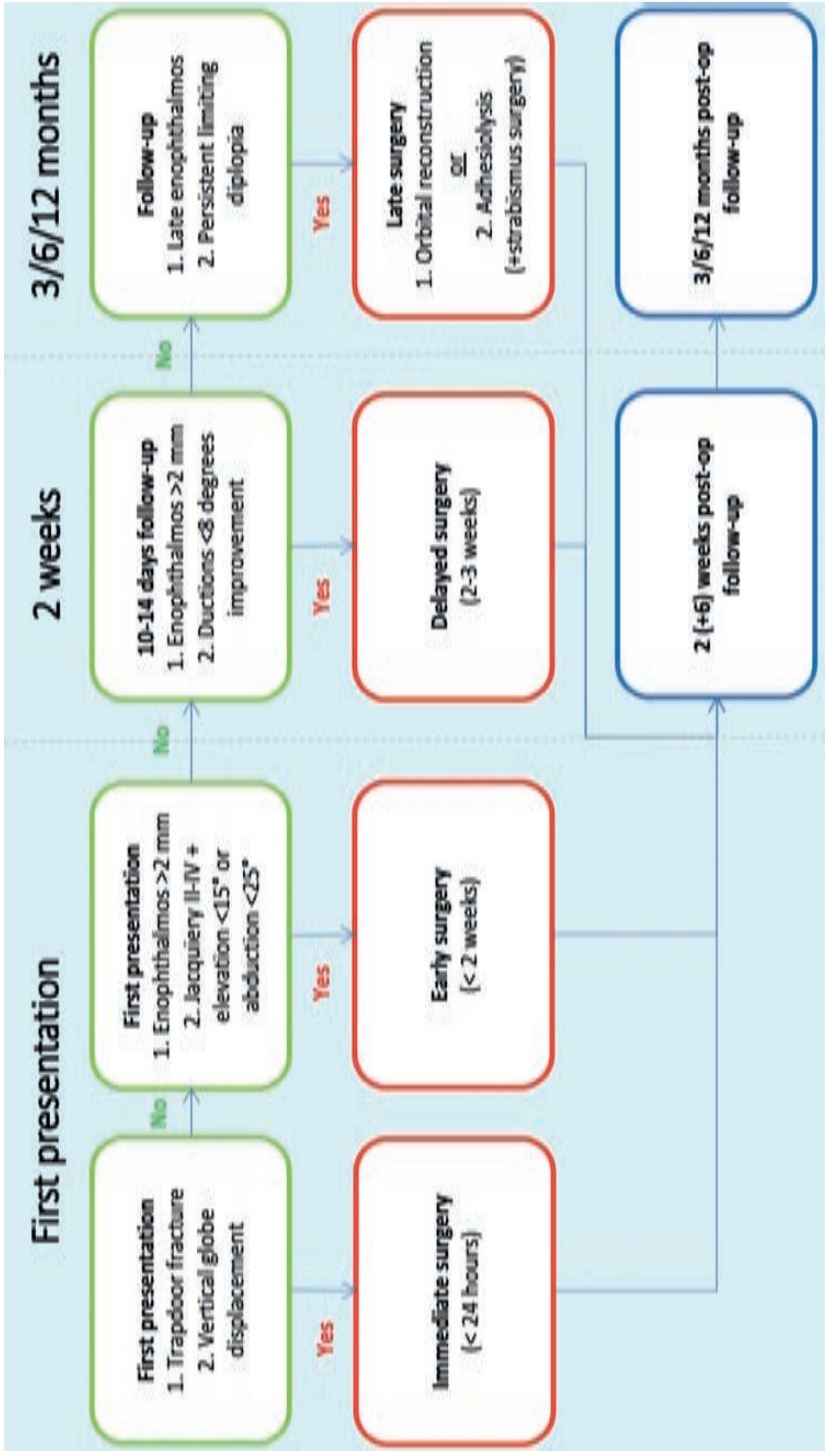


Figure 1 Study model and timeline with the nonsurgical group, including indications for surgery (green), the surgical group (red) and the post-op follow-up visits (blue).



### *Surgical group*

The indication and timing of surgery depended on the parameters outlined earlier. In all cases surgical access was via a transconjunctival approach, with or without canthotomy. Orbital defects were reconstructed using titanium implants. Any deviation, being either circumstantial or surgeon-related, was recorded. The surgeons in both hospitals were experienced in, and familiar with, all techniques used. An intraoperative or postoperative CT scan was made before discharge to check the reconstruction. A postoperative clinical examination was carried out by the oral and maxillofacial surgeon before discharge. A control visit was scheduled within 10-14 days and at 6 weeks ( $\pm$  7 days) after surgery. Further postoperative follow-up visits were scheduled identically to those for the nonsurgical group. If patients had persistent diplopia, enophthalmos, or other severe complications after surgery, a revision surgery could be indicated and was recorded if applicable. Persistent diplopia or unimproved ductions were recorded as these could lead to secondary intervention with an adhesiolysis and/or strabismus surgery.

### **Study variables**

The primary outcome was the result 3/6/12 months after first presentation or surgery. The outcome was measured by using different categories – excellent, good, acceptable, poor, failure – based on objective measurements of diplopia, enophthalmos, and complications/sequelae, as explained in Table 1. Secondary outcome measures were complications or sequelae, such as diplopia, limited ductions, and enophthalmos. The subjective outcome was recorded by a diplopia QoL questionnaire.

**Table 1** Classification of the outcomes of this study, based on the severity of diplopia, enophthalmos, and other complications or sequelae.

<b>Excellent</b>	No diplopia, enophthalmos 0-2 mm, no other complications/sequelae
<b>Good</b>	No diplopia, enophthalmos 0-2 mm, other minor complications/sequelae
<b>Acceptable</b>	Diplopia in areas score 1 (absence of head tilt), enophthalmos 0-2 mm
<b>Poor</b>	Diplopia in areas score 1/2 (absence of head tilt), enophthalmos >2 mm
<b>Failure</b>	Revision surgery due to severe disability caused by unimproved diplopia or enophthalmos, major complications/sequelae

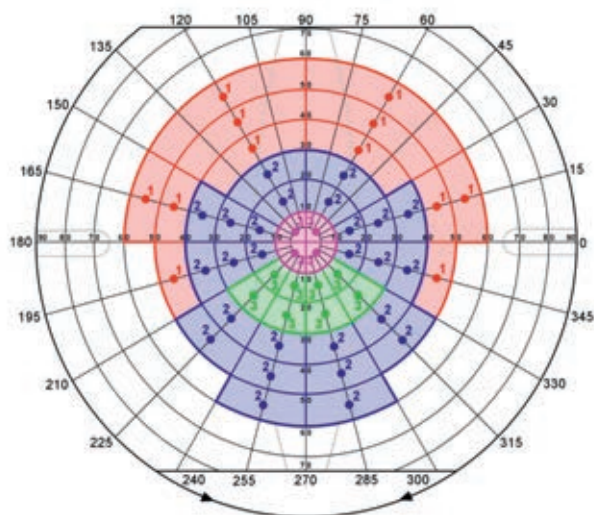
## Measurement tools

1. Fractures were classified according to the extended version of the Jaquiéry classification using the CT scan from the first visit<sup>6</sup>. The position of the fracture (orbital floor and/or medial wall) was also noted.
2. Exophthalmometry was measured by an experienced clinician using the Hertel exophthalmometer<sup>41</sup>. Enophthalmos of >2 mm was considered to be clinically significant.
3. The field of binocular single vision (BSV) was measured with a motility perimeter using an III4e light target<sup>41</sup>. The BSV was then scored at a score sheet from 0 to 100 points (Fig. 2)<sup>43-45</sup>.
4. The motility perimeter was also used to measure the ductions in all four directions of gaze - abduction, adduction, elevation, and depression. Care was taken to secure the head position of the patient accurately in the primary position<sup>46</sup>. For assessing ductions the mean difference in degrees between the affected and unaffected side was measured for the horizontal gaze (abduction + adduction) and the vertical gaze (elevation + depression).
5. The QoL questionnaire comprised the first eight questions of an existing diplopia QoL questionnaire used for Graves ophthalmopathy<sup>44,47</sup>. The questions focused on the degree of impairment of daily life activities due to the diplopia. Based on the answers, the final scores varied from 0 (completely incapacitating) to 100 (no impairment at all).

## Statistical analysis

All data were noted on patient-specific forms in both hospitals and collected in a database in Amsterdam. To adhere to data safety regulations, the results were anonymised. Statistical data analysis was performed using SPSS Statistics (version 25.0; IBM Corp., Armonk, NY, USA). Patient characteristics were described using descriptive statistics and the Fisher exact test was used to compare the nonsurgical and surgical group. Both mean and standard deviation were used to describe the continuous data for the general outcome at the end of follow-up. The Friedman test and post-hoc Wilcoxon signed-rank test were used to

analyse differences in time for outcome during follow-up. Significance was assumed when  $p < 0.05$ . The Bonferroni correction was used for the post-hoc test ( $p < 0.05/k$ ). In these cases, significance was assumed when  $p < 0.0125$  for BSV score, ductions and enophthalmos, and  $p < 0.0167$  for the QoL questionnaire.



**Figure 2** Scoring system for diplopia measured with the motility perimeter (adapted by Jellema et al., 2015 and based on Sullivan et al., 1992). Excellent: BSV in all coloured areas (89-100 points); Good: BSV in purple, green, and blue areas (38-88 points); Acceptable: BSV in purple and green areas (15-36 points); Poor: only BSV in purple area ( $\leq 12$  points); Failure: no BSV (0 points).

## Results

### Patient characteristics

Of the 70 patients who met the inclusion criteria, 58 completed follow-up of 3 months, 42 reached 6 months, and 29 were also assessed at 12 months. A total of 12 patients were lost to follow-up. The mean age was 49 years (range 20-85 years) and most patients were male (Table 2). Of the fractures, 36 were located on the left side and the main cause of trauma was violence. Nonsurgical treatment was received by 46 patients and 12 underwent surgery. Indications for surgery were enophthalmos at

first presentation (one patient) and after 2 weeks (one patient), motility disturbance combined with enophthalmos at first presentation (one patient), unimproved motility after 2 weeks (eight patients), and persistent pain and diplopia after 3 months (one patient). Neither location ( $p=1.00$ ) nor severity of the fracture ( $p=0.052$ ) were significantly different between the surgical and nonsurgical group.

**Table 2** Patient characteristics.

<b>Age (mean, range)</b>	49 years,	20-85 years	
<b>Gender</b>	Male	33 (57 %)	
	Female	25 (43 %)	
<b>Aetiology</b>	Violence	22 (38 %)	
	Fall	17 (29 %)	
	Traffic	9 (16 %)	
	Sports	8 (14 %)	
	Work	2 (3 %)	
<b>Affected side</b>	Left	36 (62 %)	
	Right	22 (38 %)	
<b>Treatment</b>	Nonsurgical	46 (79 %)	
	Surgical	12 (21 %)	
<b>Location</b>		Nonsurgical	Surgical
	Floor	31 (67 %)	8 (67 %)
	Medial	5 (11 %)	1 (8 %)
	Both	10 (22 %)	3 (25 %) ( $p=1.00$ )
<b>Severity</b>		Nonsurgical	Surgical
	I	11 (24 %)	0 (0 %)
	II	26 (57 %)	7 (58 %)
	III	8 (17 %)	3 (25 %)
	IV	1 (2 %)	2 (17 %) ( $p=0.052$ )

### General outcome at the end of follow-up

In the nonsurgical group 32 patients had an excellent outcome, with nine classed as good and five as acceptable. In the surgical group two patients had an excellent outcome, two good, two acceptable and six poor (Table 3). Differences in outcome were mainly caused by persistent diplopia and other complications or sequelae.

Diplopia was observed in five nonsurgical patients in extreme upward gaze (score 1). Mean binocular single vision (BSV) score for the nonsurgical group was 99.2 (SD 2.5) and mean quality-of-life (QoL) score was 99.0 (SD 4.3). Mean BSV and QoL scores for the five patients with diplopia in

the nonsurgical group was 92.6 (SD 2.7) and 93.8 (SD 10.8), respectively. In the surgical group eight patients had diplopia at their last visit - two in extreme upward gaze (score 1), four in upward gaze (score 1+2) and two in extreme upward and downward gaze. Mean BSV and QoL scores for the surgical group were 88.7 (SD 11.6) and 85.7 (SD 20.4), respectively. For the eight patients with diplopia mean BSV score was 83.0 (SD 10.1) and mean QoL score 78.2 (SD 23.7).

There was a maximum QoL score for 11 of the patients at their last visit. Five of the patients with diplopia in both groups experienced no subjective diplopia.

Mean vertical duction difference was -0.8 (SD 4.6) degrees for the nonsurgical group and -11.5 (SD 11.4) degrees for the surgical group. Mean horizontal duction difference was 0.1 (SD 3.7) degrees for the nonsurgical group and -2.8 (SD 4.3) degrees for the surgical group.

The mean enophthalmos was -0.76 (SD 0.67) mm and -0.58 mm (SD 0.67) for the nonsurgical and surgical group, respectively. Two patients had enophthalmos at first presentation and one patient after 2 weeks. There were no patients with significant enophthalmos at the end of follow-up.

Fifteen of all patients had one or more other complaints at their last control visit. The complications or sequelae were hypesthesia of the infraorbital nerve (eleven patients), pain (five patients), epiphora (one patient), elevated intraocular pressure (one patient) and mydriasis (one patient). Pain was observed in maximum duction or due to hyperesthesia of the infraorbital nerve.

### **BSV score during follow-up**

There was a significant improvement ( $p=0.00$ ) of BSV scores during follow-up in both nonsurgical and surgical groups (Table 4). There was a significant improvement ( $p=0.00$ ) between 2-week to 3-month control visits in the nonsurgical group. Minimum score at first presentation was 34 in the nonsurgical group and 0 in the surgical group. Maximum score at first presentation was 100 in the nonsurgical group and 85 in the surgical group.



**Table 3** Outcome at the end of follow-up.

	Nonsurgical		Surgical		Combined	
<b>Outcome</b>	Exc.	32 (70 %)	Exc.	2 (17 %)	Exc.	34 (59 %)
	Good	9 (19 %)	Good	2 (17 %)	Good	11 (19 %)
	Accept.	5 (11 %)	Accept.	2 (17 %)	Accept.	7 (12 %)
	Poor	0 (0 %)	Poor	6 (49 %)	Poor	6 (10 %)
	Fail.	0 (0 %)	Fail.	0 (0 %)	Fail.	0 (0 %)
<b>Diplopia</b>	Yes	5 (11 %)	Yes	8 (67 %)	Yes	13 (22 %)
	No	41 (89 %)	No	4 (33 %)	No	45 (78 %)
<b>Hypesthesia</b>	Yes	8 (17 %)	Yes	3 (25 %)	Yes	11 (19 %)
	No	38 (83 %)	No	9 (75 %)	No	47 (81 %)
<b>Pain</b>	Yes	4 (9 %)	Yes	1 (8 %)	Yes	5 (9 %)
	No	42 (91 %)	No	11 (92 %)	No	53 (91 %)
<b>Other</b>	Yes	1 (2 %)	Yes	2 (17 %)	Yes	3 (5 %)
	No	45 (98 %)	No	10 (83 %)	No	55 (95 %)
<b>BSV score</b>	99.2 (SD 2.5)		88.7 (SD 11.6)		97.0 (SD 7.0)	
<b>QoL score</b>	99.0 (SD 4.3)		85.7 (SD 20.4)		96.6 (SD 10.5)	
<b>Δ Hor. duction</b>	0.1 (SD 3.7)		-2.8 (SD 4.3)		-0.5 (SD 4.0)	
<b>Δ Vert. duction</b>	-0.8 (SD 4.6)		-11.5 (SD 11.4)		-3.0 (SD 7.8)	
<b>Enophthalmos</b>	-0.8 mm (SD 0.7)		-0.6 mm (SD 0.7)		-0.7 mm (SD 0.7)	

### Ductions during follow-up

There was a significant improvement ( $p=0.04$ ) in horizontal duction difference in the nonsurgical group (Table 4). A significant difference ( $p=0.01$ ) was observed in the nonsurgical group between first presentation and 2 weeks. This difference was not found in the surgical group. The vertical duction difference showed a significant improvement ( $p=0.00$ ) in the nonsurgical group, with a significant ( $p=0.00$ ) change between first presentation and 2 weeks.

Table 4 BSV/QoL score,  $\Delta$  horizontal/vertical ductions (degrees) and enophthalmos (millimetres) during follow-up.

	First pres.	2 weeks	3 months	6 months	12 months
<b>BSV (n=23)</b>					
<i>Nonsurgical (n=17)</i>	86.7 (SD 15.7)	91.9 (SD 8.0)	96.1 (SD 5.4)	97.2 (SD 4.6)	98.5 (SD 3.3)
<i>Surgical (n=6)</i>	58.7 (SD 28.7)	62.0 (SD 25.1)	76.5 (SD 12.5)	85.3 (SD 12.2)	87.5 (SD 7.1)
<b>QoL (n=19)</b>					
<i>Nonsurgical (n=14)</i>	-	87.2 (SD 20.7)	93.3 (SD 13.0)	97.7 (SD 6.0)	100 (SD 0.0)
<i>Surgical (n=5)</i>	-	81.4 (SD 21.2)	85.0 (SD 22.4)	83.8 (SD 23.2)	85.0 (SD 22.4)
<b><math>\Delta</math> Hor. Ductions (n=26)</b>					
<i>Nonsurgical (n=17)</i>	-7.3 (SD 11.0)	-1.1 (SD 8.7)	-4.8 (SD 7.7)	-0.5 (SD 6.3)	-0.1 (SD 4.0)
<i>Surgical (n=9)</i>	-5.6 (SD 8.6)	-7.6 (SD 8.6)	-4.8 (SD 7.7)	-4.9 (SD 5.8)	-2.3 (SD 4.7)
<b><math>\Delta</math> Vert. ductions (n=26)</b>					
<i>Nonsurgical (n=17)</i>	-10.0 (SD 11.6)	-4.1 (SD 8.4)	-2.4 (SD 10.0)	1.3 (SD 5.2)	-1.4 (SD 5.9)
<i>Surgical (n=9)</i>	-23.3 (SD 13.8)	-18.3 (SD 12.5)	-14.2 (SD 12.2)	-12.1 (SD 10.2)	-12.7 (SD 11.2)
<b>Enophthalmos (n=28)</b>					
<i>Nonsurgical (n=19)</i>	-0.8 (SD 1.0)	-0.6 (SD 1.0)	-1.0 (SD 0.8)	-1.1 (SD 0.9)	-0.9 (SD 0.7)
<i>Surgical (n=9)</i>	-1.1 (SD 1.4)	0.3 (SD 1.0)	-0.7 (SD 0.9)	-0.7 (SD 0.5)	-0.4 (SD 0.9)

### QoL score during follow-up

QoL significantly improved ( $p=0.00$ ) in the nonsurgical group with a significant improvement ( $p=0.00$ ) between 2 weeks and 3 months. There was no significant improvement in the surgical group. The minimum score 2 weeks after trauma or surgery was 25 in the nonsurgical group and 50 in the surgical group. The maximum score was 100 in both groups.

### Enophthalmos during follow-up

There was a significant difference ( $p=0.03$ ) in enophthalmos at follow-up in the surgical group (Table 4). Maximum enophthalmos at first presentation was -2 mm in the nonsurgical group and -3 mm in the surgical group. Maximum enophthalmos at last visit was -2 mm in the nonsurgical group and -1 mm in the surgical group.

### Comparison between included patients and drop-outs

Table 5 illustrates the comparisons between the 58 included patients and the 12 drop-outs who were lost to follow-up. The groups were comparable, except for age, gender, and aetiology.

**Table 5** Comparison between included patients and drop-outs.

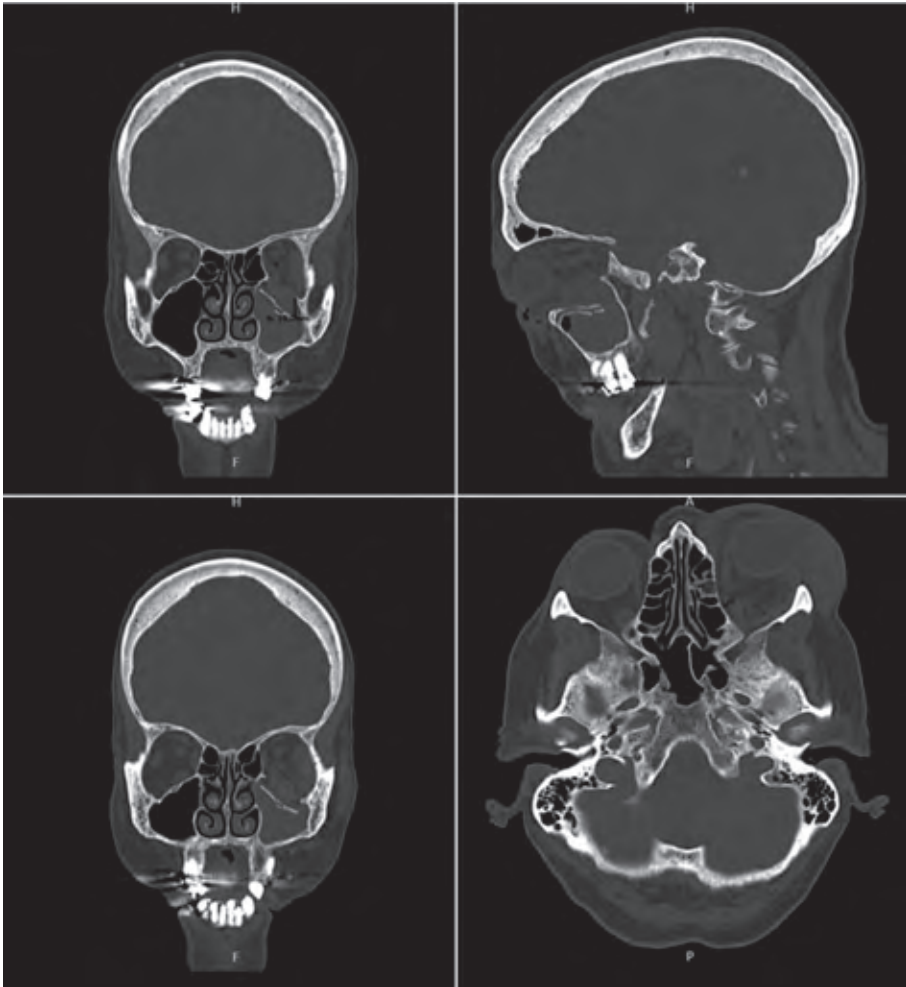
	Included patients (58)		Drop-outs (12)	
<b>Age (mean, range)</b>	49 years,	20-85 years	39 years,	22-78 years
<b>Gender</b>	Male	33 (57 %)	Male	10 (83 %)
	Female	25 (43 %)	Female	2 (17 %)
<b>Aetiology</b>	Violence	22 (38 %)	Violence	6 (50 %)
	Fall	17 (29 %)	Fall	1 (8 %)
	Traffic	9 (16 %)	Traffic	0 (0 %)
	Sports	8 (14 %)	Sports	5 (42 %)
	Work	2 (3 %)	Work	0 (0 %)
<b>Affected side</b>	Left	36 (62 %)	Left	6 (50 %)
	Right	22 (38 %)	Right	6 (50 %)
<b>Treatment</b>	Nonsurgical	46 (79 %)	Nonsurgical	10 (83 %)
	Surgical	12 (21 %)	Surgical	2 (17 %)
<b>Location</b>	Floor	39 (67 %)	Floor	7 (58 %)
	Medial	6 (10 %)	Medial	2 (17 %)
	Both	13 (23 %)	Both	3 (25 %)
<b>Severity</b>	I	11 (24 %)	I	3 (25 %)
	II	33 (57 %)	II	6 (50 %)
	III	11 (17 %)	III	3 (25 %)
	IV	3 (2 %)	IV	0 (0 %)
<b>Diplopia</b>	Yes	35 (60 %)	Yes	7 (58 %)
	No	23 (40 %)	No	5 (42 %)
<b>BSV score</b>	82.8 (SD 25.6)		80.8 (SD 32.2)	
<b>Δ Hor. duction</b>	-6.3 (SD 10.0)		-8.1 (SD 12.3)	
<b>Δ Vert. duction</b>	-11.8 (SD 12.6)		-10.4 (SD 22.4)	
<b>Enophthalmos</b>	-0.7 mm (SD 1.1)		-0.6 mm (SD 1.1)	

## Discussion

This prospective cohort study showed promising results for the nonsurgical management of orbital blow-out fractures in a multidisciplinary setting. The purpose of this study was to evaluate a well-defined clinical protocol for orbital floor and/or medial wall fractures. The authors hypothesised that emphasis on nonsurgical management based on orthoptic evaluation would result in good clinical outcome. The first study that presented follow-up of patients with and without surgical repair was in 1971<sup>1</sup>. There was no significant difference in enophthalmos or persistent diplopia in both groups. Since then several authors propagated a nonsurgical approach<sup>2-4,6,7,20</sup>. Studies have demonstrated significant bias resulting from different treatment approaches, with variations evident across countries, hospitals, and even specialists<sup>9,10,48</sup>. The aim of this prospective cohort study was to move further towards a standardised treatment protocol based on clinical evidence.

The patient characteristics were similar to those in other studies, with the study population being a representative sample of the general population<sup>18,21,49</sup>. Most patients (79 %) had no surgery, based on the predetermined criteria in the protocol, which was in line with the emphasise on a nonsurgical approach. Both location and severity of the fractures were comparable across the nonsurgical and surgical groups.

The results in the nonsurgical group were promising. All patients had an excellent, good, or acceptable outcome at the end of follow-up. There were several large fractures in the nonsurgical group (Fig. 3) that might have had an indication for surgery with earlier clinical protocols, but now appeared to recover completely without enophthalmos. The outcome of this study does not support the principles of defect-driven treatment to prevent enophthalmos.



**Figure 3** CT scan of a nonsurgical patient with good clinical outcome (no enophthalmos / diplopia, only a sequela of persistent infraorbital nerve hypesthesia).

The outcome in the surgical group was worse, with 51 % excellent, good, or acceptable results, and the other patients had poor results. No patients experienced an outcome failure, because there was no revision surgery necessary. It should be noted that the surgical group had worse orthoptic measurements to begin with, which might have contributed to incomplete recovery<sup>17,20</sup>. It is also likely that the additional trauma of the surgery itself caused sequelae due to adhesions and fibrosis. Another important observation is that although the results were poor in 49 % of

the patients, the binocular single vision (BSV) scores and quality-of-life (QoL) scores were high in these groups.

In 75 % of the patients in the surgical group, surgery was performed between 2 and 3 weeks. Two patients were treated within a week due to early enophthalmos or seriously limited ductions. One patient had surgery after 3 months due to persisting pain, which was believed to be related to infraorbital nerve dysesthesia.

The difference between excellent and good outcome was the presence of minor complications or sequelae. In the nonsurgical group infraorbital nerve hypesthesia, pain, and/or epiphora were recorded, while some in the surgical group experienced infraorbital nerve hypesthesia, pain, elevated intraocular pressure, and mydriasis. None of the complications led to impaired vision. The percentages of those complications or sequelae were comparable to other studies<sup>18,24,50</sup>.

The strength of this prospective research included the systematic and objective orthoptic evaluations in follow-up, and the use of various parameters to evaluate the surgical and nonsurgical results - both objective and subjective. Across the complete cohort 13 patients had residual diplopia, yet in only eight patients (three nonsurgical/five surgical) did this affect their daily activities, based on the QoL score. This difference between objective and subjective outcomes was also reported by Dietz et al.<sup>51</sup>. Patients seem to become accustomed to diplopia in extreme gaze, which may gradually decrease impairment over several months. The QoL score improved the most in the nonsurgical group, between 2 weeks and 3 months follow-up. In the nonsurgical group, the BSV score was high at the end of follow-up. These results confirm the outcome of other studies propagating nonsurgical management<sup>6,22,37</sup>.

In the surgical group, the BSV scores could still be considered acceptable to high (Alhamdani et al., 2015). Although none of the patients had diplopia in central gaze and 30 degrees in every direction, daily activities were partially limited in several patients. In most cases it was in extreme upward and downward gaze, with the downward limitation considered

to be more incapacitating. BSV scores improved gradually in both groups up to 12 months follow-up, with a significant improvement in the postoperative period 2 weeks to 3 months. This gradual improvement of diplopia confirmed the findings in similar studies<sup>20,52</sup>.

Limitations in horizontal ductions were less extensive than limitations in vertical ductions. An alleged reason for this was that most of the fractures involved the orbital floor. Limitations in vertical duction were greater in the surgical group at first presentation (-23.3 degrees, SD 13.8) compared with the nonsurgical group (-10.0 degrees, SD 11.6). Both groups showed improvement over time, however, the improvement was only statistically significant in the nonsurgical group. Bianchi et al. conclude that incomitance was associated with the severity of the fracture and long-term diplopia<sup>21</sup>. This could explain the patients with a poor outcome in the surgical group.

The QoL score is unique, with patient-related outcome measurements rarely used in orbital trauma research. Quality of life was previously described following orbital decompression surgery in Graves patients<sup>53</sup>. An increase in score of 6-10 points after decompression or strabismus surgery was seen as an improvement by the patient<sup>54</sup>. It is not possible to compare scores before and after trauma, but changes over time could clearly be identified in this study. Folkestad et al. stated in their report on zygomatico-orbital fractures that diplopia 12 months postoperatively was not experienced as a major problem as it was usually only present in extreme vertical gaze<sup>55</sup>. The diplopia QoL score may prove to become an important patient-related measure in evaluating trauma treatment strategies<sup>56</sup>.

No significant increase in enophthalmos was found in the nonsurgical group. The observed significant difference in the surgical group is believed to be caused by a decrease in enophthalmos following surgery. Late enophthalmos did not develop in both the nonsurgical and surgical groups. This may be noteworthy as there were several large defects in the nonsurgical group (Fig. 3). Young et al. state that, over time, a decrease in fracture size and a reduction in orbital herniation may be possible<sup>57</sup>.

Tendon and ligamentous support might also be sufficient to keep the soft tissue in place<sup>3</sup>. In some studies the incidence of enophthalmos might have been higher due to differences in severity of the fractures<sup>6,15,22,32</sup>. Based on the findings of this study, there is no justification in indicating surgery based on CT imaging alone.

The multidisciplinary nature of the investigators in this study allowed the combination of available expertise from all three specialties in the development of the clinical protocol and during follow-up. This cooperation also presented challenges, mainly in terms of communication and logistics, which took effort and time. In retrospect, an aesthetic QoL questionnaire for enophthalmos could have added value to this research. This may be incorporated in future studies. The patients in this study were not randomised, because it was an observational study with a single clinical protocol. Future randomisation with different clinical protocols may very well increase the scientific strength in comparison with this study. Further studies may also need larger numbers and more centres, with concomitant logistics and cooperation. The drop-out of 17 % was substantial, but not surprising. Trauma patients treated in an acute setting are known for high losses to follow-up<sup>58</sup>. Nonsurgical treatment, absence of symptoms, and intense and time-consuming orthoptic evaluation may decrease commitment to studies in general.

We hypothesise, that as long as the musculofibrous network of the globe is relatively undamaged, orbital fractures heal spontaneously without significant motility disturbance or enophthalmos. Whether or not this supportive framework is severely damaged, appears as a function of eye motility. Change of motility therefore is an important predictor of outcome of orbital fractures.

Based on these outcomes, our recommendations in orbital wall fractures are:

1. To postpone surgery for at least 2 weeks in absence of an acute indication or early enophthalmos. It may even be worth considering a wait of 3 months, since significant improvements can still be observed during this period.



2. Surgery should not be performed in anticipation of expected posttraumatic complications, such as persistent diplopia or enophthalmos. The patient should be informed that improvement is possible for up to 12 months, and the risk of late enophthalmos, even in large fractures, is minimal.
3. If enophthalmos does occur, surgery may still be indicated.

## Conclusion

A nonsurgical approach is a safe treatment strategy for most orbital floor and/or medial wall fractures, and may prevent surgery-related complications. It is important to perform repeated quantitative evaluation of ocular motility in the first 3 months after trauma, with the most expected improvement in the first 2 weeks. Immediate indications aside, surgery is only recommended for insufficiently improved orthoptic measurements or early development of enophthalmos. Improvement is observed up to 12 months in binocular single vision, ductions, and the subjective experience of diplopia. A multidisciplinary approach is important to achieve the highest standard of care and to gain more insight into the complex recovery of these fractures. Future prospective research should be focused on quantitative measurements combined with subjective outcomes.

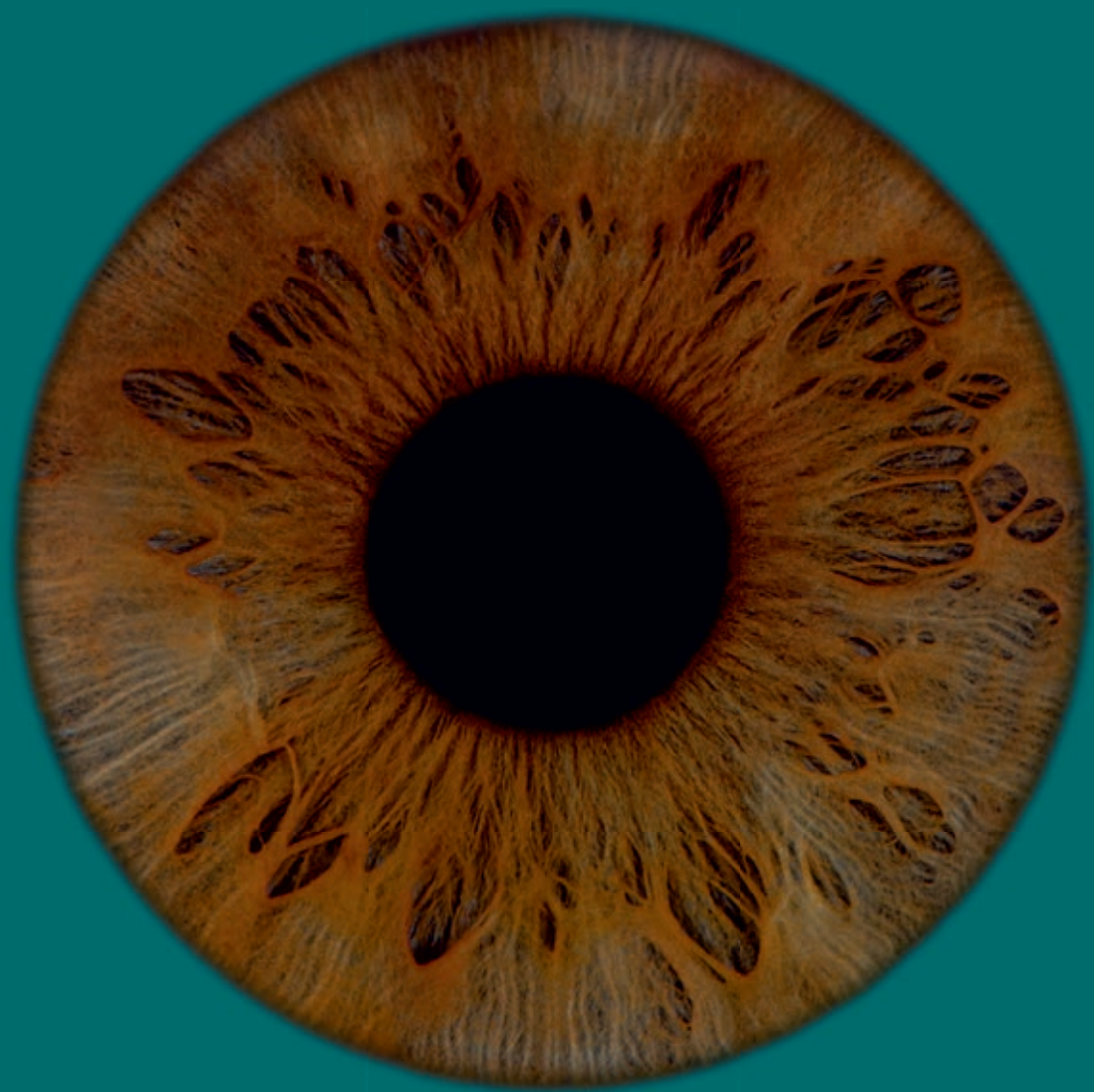## References

1. Emery JM, Noorden GK, Sclernitzauer DA: Orbital floor fractures: long-term follow-up of cases with and without surgical repair. *Trans Am Acad Ophthalmol Otolaryngol* 75: 802-812, 1971
2. Putterman AM, Stevens T, Urist MJ: Nonsurgical management of blow-out fractures of the orbital floor. *Am J Ophthalmol* 77: 232-239, 1974
3. Koornneef L: Current concepts on the management of orbital blow-out fractures. *Ann Plast Surg* 9: 185-200, 1982
4. Everhard-Halm YS, Koornneef L, Zonneveld FW: Conservative therapy frequently indicated in blow-out fractures of the orbit. *Ned Tijdschr Geneesk* 135: 1226-1228, 1991
5. Burnstine MA: Clinical recommendations for repair of isolated orbital floor fractures: an evidence-based analysis. *Ophthalmology* 109: 1207-1210, 2002
6. Kunz C, Sigron GR, Jaquiéry C: Functional outcome after nonsurgical management of orbital fractures - the bias of decision-making according to size of defect: critical review of 48 patients. *Br J Oral Maxillofac Surg* 51: 486-492, 2013
7. Beigi B, Khandwala M, Gupta D: Management of pure orbital floor fractures: a proposed protocol to prevent unnecessary or early surgery. *Orbit* 33: 336-342, 2014
8. Dubois L, Steenen SA, Gooris PJJ, et al.: Controversies in orbital reconstruction - I. Defect-driven orbital reconstruction: a systematic review. *Int J Oral Maxillofac Surg* 44: 308-315, 2015
9. Aldekhayel S, Aljaaly H, Fouda-Neel O, et al.: Evolving trends in the management of orbital floor fractures. *J Craniofac Surg* 25: 258-261, 2014
10. Christensen BJ, Zaid W: Inaugural survey on practice patterns of orbital floor fractures for American oral and maxillofacial surgeons. *J Oral Maxillofac Surg* 74: 105-122, 2016
11. Dubois L, Jansen J, Schreurs R, et al.: How reliable is the visual appraisal of a surgeon for diagnosing orbital fractures? *J Craniomaxillofac Surg* 44: 1015-1024, 2016
12. Vicinanza MG, McGwin Jr G, Allamneni C, et al.: Interreader variability of computed tomography for orbital floor fracture. *JAMA Ophthalmol* 133: 1393-1397, 2015
13. Goggin J, Jupiter DC, Czerwinski M: Simple computed tomography-based calculations of orbital floor fracture defect size are not sufficiently accurate for clinical use. *J Oral Maxillofac Surg* 73: 112-116, 2015
14. Choi SH, Kang DH: Prediction of late enophthalmos using preoperative orbital volume and fracture area measurements in blowout fracture. *J Craniofac Surg* 28: 1717-1720, 2017
15. Schönegg D, Wagner M, Schumann P, et al.: Correlation between increased orbital volume and enophthalmos and diplopia in patients with fractures of the orbital floor or the medial orbital wall. *J Craniomaxillofac Surg* 46: 1544-1549, 2018
16. Ahmad Nasir S, Ramli R, Abd Jabar N: Predictors of enophthalmos among adult patients with pure orbital blowout fractures. *PLoS One* 13: e0204946, 2018
17. Tahiri Y, Lee J, Tahiri M, et al.: Preoperative diplopia: the most important prognostic factor for diplopia after surgical repair of pure orbital blowout fracture. *J Craniofac Surg* 21: 1038-1041, 2010
18. Bartoli D, Fadda MT, Battisti A, et al.: Retrospective analysis of 301 patients with orbital floor fracture. *J Craniomaxillofac Surg* 43: 244-247, 2015
19. Su Y, Shen Q, Lin M, et al.: Predictive factors for residual diplopia after surgical repair in pediatric patients with orbital blowout fracture. *J Craniomaxillofac Surg* 44: 1463-1468, 2016
20. Alhamdani F, Durham J, Greenwood M, et al.: Diplopia and ocular motility in orbital blow-out fractures: 10-year retrospective study. *J Craniomaxillofac Surg* 43: 1010-1016, 2015
21. Bianchi F, De Haller R, Steffen H, et al.: Does vertical incomitance predict the diplopia outcome in orbital fracture patients? A prospective study of 188 patients. *J Craniomaxillofac Surg* 47: 305-310, 2019

22. Hwang K, Huan F, Hwang PJ: Diplopia and enophthalmos in blowout fractures. *J Craniofac Surg* 23: 1077-1082, 2012
23. Matteini C, Renzi G, Becelli R, et al.: Surgical timing in orbital fracture treatment: experience with 108 consecutive cases. *J Craniofac Surg* 15: 145-150, 2004
24. Scawn RL, Lim LH, Whipple KM, et al.: Outcomes of orbital blow-out fracture repair performed beyond 6 weeks after injury. *Ophthal Plast Reconstr Surg* 32: 296-301, 2016
25. Damgaard OE, Larsen CG, Felding UA, et al.: Surgical timing of the orbital "blowout" fracture: a systematic review and meta-analysis. *Otolaryngol Head Neck Surg* 155: 387-390, 2016
26. McRae M, Augustine HFM, Budning A, et al.: Functional outcomes of late post-traumatic enophthalmos correction. *Plastic and Reconstructive Surgery* 142: 169e-178e, 2018
27. Safi AF, Richter MT, Rothamel D, et al.: Influence of the volume of soft tissue herniation on clinical symptoms of patients with orbital floor fractures. *J Craniomaxillofac Surg* 44: 1929-1934, 2016
28. Zimmerer RM, Ellis E, Aniceto GS, et al.: A prospective multicenter study to compare the precision of posttraumatic internal orbital reconstruction with standard preformed and individualized orbital implants. *J Craniomaxillofac Surg* 44: 1485-1497, 2016
29. Hawes MJ, Dortzbach RK: Surgery on orbital floor fractures. Influence of time of repair and fracture size. *Ophthalmology* 90: 1066-1070, 1983
30. Dal Canto AJ, Linberg JV: Comparison of orbital fracture repair performed within 14 days versus 15 to 29 days after trauma. *Ophthal Plast Reconstr Surg* 24: 437-443, 2008
31. Dubois L, Steenen SA, Gooris PJJ, et al.: Controversies in orbital reconstruction - II. Timing of post-traumatic orbital reconstruction: a systematic review. *Int J Oral Maxillofac Surg* 44: 433-440, 2015
32. Zhang S, Gui H, Lin Y, et al.: Navigation-guided correction of midfacial post-traumatic deformities (Shanghai experience with 40 Cases). *J Oral Maxillofac Surg* 70: 1426-1433, 2012
33. Snäll J, Narjus-Sterba M, Toivari M, et al.: Does postoperative orbital volume predict postoperative globe malposition after blow-out fracture reconstruction? A 6-month clinical follow-up study. *Oral Maxillofac Surg* 23: 27-34, 2019
34. Brucoli M, Arcuri F, Cavenaghi R, Benech A: Analysis of complications after surgical repair of orbital fractures. *J Craniofac Surg* 22: 1387-1390, 2011
35. Boyette JR, Pemberton JD, Bonilla-Velez J: Management of orbital fractures: challenges and solutions. *Clin Ophthalmol* 9: 2127-2137, 2015
36. Giroto JA, Gamble WB, Robertson B, et al.: Blindness after reduction of facial fractures. *Plast Reconstr Surg* 102: 1821-1834, 1998
37. Gosse EM, Ferguson AW, Lymburn EG, et al.: Blow-out fractures: patterns of ocular motility and effect of surgical repair. *Br J Oral Maxillofac Surg* 48: 40-43, 2009
38. Pansell T, Alinasab B, Westermarck A, et al.: Ophthalmologic findings in patients with nonsurgically treated blowout fractures. *Craniomaxillofac Trauma Reconstr* 5: 1-6, 2012
39. Devoe AG: Fractures of the orbital floor. *Trans Am Ophthalmol Soc* 45: 502-526, 1947
40. Jaquiéry C, Aeppli P, Cornelius P, et al.: Reconstruction of orbital wall defects: critical review of 72 patients. *Int J Oral Maxillofac Surg* 36: 193-199, 2007
41. Mourits MP, Lombado SH, van der Sluijs FA, et al.: Reliability of exophthalmos measurement and the exophthalmometry value distribution in a healthy Dutch population and in Graves' patients. An exploratory study. *Orbit* 23: 161-168, 2004
42. Woodruff G, O'Reilly C, Kraft SP: Functional scoring of the field of binocular single vision in patients with diplopia. *Ophthalmology* 94: 1554-1561, 1987
43. Sullivan TJ, Kraft SP, Burack C, et al.: A functional scoring method for the field of binocular single vision. *Ophthalmology* 99: 575-581, 1992
44. Mourits MP, Prummel MF, Wiersinga WM, et al.: Measuring eye movements in Graves ophthalmopathy. *Ophthalmology* 101: 1341-1346, 1994

45. Jellema HM, Braaksma-Besselink Y, Limpens J, et al.: Proposal of success criteria for strabismus surgery in patients with Graves' orbitopathy based on a systematic literature review. *Acta Ophthalmol* 93: 601-609, 2015
46. Jellema HM, Baader A, Pitz S, et al.: Comparison of cyclodeviation and duction measurement in Graves' Orbitopathy patients using different devices. *Strabismus* 19: 43-51, 2011
47. Terwee CB, Gerding MN, Dekker FW, et al.: Development of a disease specific quality of life questionnaire for patients with Graves' ophthalmopathy: the GO-QOL. *Br J Ophthalmol* 82: 772-779, 1998
48. Alinasab B, Ryott M, Stjärne P: Still no reliable consensus in management of blow-out fracture. *Injury* 45: 197-202, 2014
49. Steinegger K, De Haller R, Courvoisier D, et al.: Orthoptic sequelae following conservative management of pure blowout orbital fractures: anecdotal or clinically relevant? *J Craniofac Surg* 26: 433-437, 2015
50. Gosau M, Schoneich M, Draenert FG, et al.: Retrospective analysis of orbital floor fractures - complications, outcome, and review of literature. *Clin Oral Investig* 15: 305-313, 2011
51. Dietz A, Ziegler CM, Dacho A, et al.: Effectiveness of a new perforated 0.15 mm poly-p-dioxanon-foil versus titanium-dynamic mesh in reconstruction of the orbital floor. *J Craniomaxillofac Surg* 29: 82-88, 2001
52. Cai EZ, Koh YP, Hing ECH, et al.: Computer-assisted navigational surgery improves outcomes in orbital reconstructive surgery. *J Craniofac Surg* 23: 1567-1573, 2012
53. Iacobaeus L, Sahlin S: Evaluation of quality of life in patients with Graves' ophthalmopathy, before and after orbital decompression. *Orbit* 35: 121-125, 2016
54. Terwee CB, Dekker FW, Mourits MP, et al.: Interpretation and validity of changes in scores on the Graves' ophthalmopathy quality of life questionnaire (GO-QOL) after different treatments. *Clin Endocrinol* 54: 391-398, 2001
55. Folkestad L, Aberg-Bengtsson L, Granström G: Recovery from orbital floor fractures: a prospective study of patients' and doctors' experiences. *Int J Oral Maxillofac Surg* 35: 499-505, 2006
56. Sharma G, Kaur A: Quality of life after orbito-facial trauma. *Orbit* 36: 407-410, 2017
57. Young SM, Kim YD, Kim SW, et al.: Conservatively treated orbital blowout fractures. *Ophthalmology* 125: 938-944, 2018
58. Aaland MO, Marose K, Zhu TH: The lost to trauma patient follow-up: a system or patient problem. *J Trauma Acute Care Surg* 73: 1507-1511, 2012





C  
H  
A  
P  
T  
E  
R

7

**General discussion  
and future perspectives**





## General discussion

Orbital wall fractures have a wide variety of treatment strategies with differences in diagnostics, indications and timing of surgery, required technological support, surgical approach, and materials used. Orbital wall fractures can range from simple to highly complex. In most cases, it is difficult to predict to what extent sequelae, such as enophthalmos and diplopia, develop or persist. Due to a high degree of heterogeneity between studies, there is an ongoing debate with regard to many aspects of treatment<sup>1</sup>. The aim of this PhD thesis is twofold. Computer-assisted surgery (CAS) has become increasingly important in supporting the surgeon during planning and treatment. In the first part of this thesis several components of CAS are evaluated. The individual components of computer-assisted diagnostics, preoperative planning, and intraoperative imaging provide valuable insight. The second part of this thesis reveals the outcome of an updated evidence-based treatment protocol. The proposed clinical protocol, with a predominantly conservative approach, shows promising results. It may serve as a scientific foundation towards uniform and multidisciplinary treatment strategies.

### Computer-assisted orbital reconstruction

Technological advancements help to refine treatment within the field of oral and maxillofacial surgery. CAS is implemented and being further developed in almost all subspecialties, including traumatology, implantology, oncology, and orthognathic surgery<sup>2</sup>. In orbital wall reconstruction, it is accountable for more accurate and predictable surgery and better clinical outcomes<sup>3-5</sup>. Recent research in CAS for orbital reconstruction is mainly aimed at improving the complete workflow, including all preoperative and intraoperative components, to explore the limits of precision. CAS has already proved to be valuable in clinical practice and can be used:

1. to clarify the fracture and the surgical plan for the patient
2. as a diagnostic tool to assess and quantify the fracture complexity
3. for preoperative virtual planning of the surgery



4. to design surgical templates, cutting guides, and patient-specific implants
5. for intraoperative navigation and imaging
6. for postoperative evaluation
7. as a learning tool for inexperienced surgeons, students, and assistants
8. for research purposes

The complete package of software and hardware, including additive manufacturing (e.g. three-dimensional [3D] printing), a navigation system, and a computed tomography (CT) scanner for intraoperative use, is required to utilise all these features. This is expensive and involves numerous adjustments in daily clinical practice, such as a time-consuming preoperative planning phase, availability of onsite technological support, and adjustments of the preoperative scan protocol to include navigational markers. It is questionable whether this is feasible and necessary in every clinic and for all patients. It is important to critically assess if the costs and efforts outweigh the improved clinical outcomes and quality of life. By performing research on the individual components of CAS, it is possible to identify the important components. When individual components are successful, it might be worthwhile to apply these more widely in general clinics. Nevertheless, it is advisable to refer complex fractures to well-equipped tertiary clinics.

### **Virtual diagnostics and preoperative planning**

Virtual diagnostics and preoperative planning software enable the surgeon to visualise the fracture in both 3D reconstruction and multiplanar views to carry out accurate measurements. An orbital wall fracture can result in an increase in volume of the orbital cavity. Enophthalmos might develop due to this volume increase. Measuring the volume provides insight into the severity of the fracture and is important in the diagnostic process. The semi-automatic method SA (automatic segmentation minus bone and air masks) proposed in chapter 2 contains the best combination of practical features to measure the volume of the intact bony orbit. The method is quick, accurate, and reproducible. The mean difference of 0.24 cc (SD 0.27) compared to the gold standard is small, especially in

comparison to other studies<sup>6,7</sup>. It is useful for research purposes and in the analysis of volume before, for example, orbital decompression surgery or reconstruction after exenteration surgery. It may also be possible to compare the postoperative volume of the reconstructed side of an orbital wall fracture with the unaffected side to quantify the volume reduction. Orbital wall fractures are often reconstructed using titanium orbital reconstruction plates. As the density of a titanium orbital implant is high and induces little scattering on a CT scan, measuring the volume after reconstruction is possible. Accuracy studies to prove the validity of measuring postoperative orbital cavities have not been performed yet.

The bony orbit is not an enclosed space due to the presence of apertures and therefore it is difficult to measure the volume. The fracture itself is an additional and irregular opening. The consequence is that measurement of the orbital volume after trauma is even more complicated. Imaginary planes and lines are necessary to delineate the fissures, optic canal, anterior boundary, and the fracture site. One solution may be to use method SAA with automatic segmentation minus bone and air masks followed by manual adjustments<sup>8,9</sup>. Although this method is not as quick and accurate, the reproducibility is high and it will still be useful in clinical assessment. This has been confirmed by a recent study with an intraclass correlation of 0.933<sup>9</sup>. The importance of measuring volume is rather to objectify the extensiveness of the fracture in comparison to the unaffected side than it is to predict the outcome or serve as an indicator for surgery.

Mirroring of the segmented unaffected bony orbit onto the fractured bony orbit is an important step in computer-assisted orbital reconstruction. It is assumed that both sides are identical and that the virtual template of the mirrored side can be a representation of the pretraumatised state of the affected side. Chapter 3 proves that the volume difference between the left and right orbital cavities is negligible and the orbital wall contours show high similarity. The mean orbital volume was 27.53 cc (SD 3.11) and the mean difference between the left and right cavity was 0.44 cc (SD 0.31). These results are comparable to other recent studies and probably differ mildly due to variation in measurement methods<sup>10-12</sup>. The largest asymmetry in the contour is noticed near the apex. This is



clinically irrelevant as this area is rarely affected by trauma. An exact anatomical restoration of the contour of the orbital floor and medial wall is impossible when using a preformed titanium implant. Therefore, small variations of the contralateral side in orbital shape are acceptable. After mirroring over the midsagittal plane, it is possible to perform a virtual reconstruction. Virtual templates of the available implants can be used to determine which implant has the best fit and thus facilitates an optimal reconstruction. The mirrored orbital cavity can also be used for the design of a patient-specific implant to get a closer approximation of the anatomy before trauma. The mirroring technique is a fundamental process in restoring the bony orbit and is one of the pillars of virtual preoperative planning.

### **Intraoperative assistance and control**

In surgical cases for orbital reconstruction, advanced diagnostics is followed by the execution and completion of the preoperative plan. Based on the size of the bony orbit and the fracture, the correct implant size will be selected using the virtual template of the preformed implants. The ideal position of the implant can be achieved with the virtual template obtained from the mirroring technique. The 3D reconstruction contributes to a better visualisation of the anatomy and assessment of the ideal position of the implant compared to the anatomical landmarks. During the virtual reconstruction 2D and 3D images can be used alternately to identify the most important landmarks, examine the boundaries of the fracture, and assess the expected problems. This is particularly insightful for an inexperienced surgeon and valuable for specialty trainees. In **chapter 4**, the preoperative plan is used as virtual guidance during surgery. Even without real-time feedback of intraoperative navigation, there is a significant improvement of the position of the implant. The accuracy is close to the outcomes of a comparable cadaver study on intraoperative navigation<sup>13</sup>. This may be due to a lack of a calibration error, adequate preparation, gaining experience during virtual reconstruction, and also because the planning can be used as a reference intraoperatively. The preoperative plan can be considered the most important step in CAS. An additional benefit of preoperative planning is that the plan can be used in the postoperative analysis to check if the targeted position is achieved. It

may also function as a tool in decision-making for a referral to a tertiary clinic if a preformed implant is undesirable and a patient-specific implant or intraoperative navigation is required.

The complete workflow of CAS is essential for intermediate to complex orbital wall fractures. Individual use of several software components already improves the clinical result and can be used for simple fractures, if the necessary hardware is unavailable, or when it is not possible to refer to a tertiary clinic. The components of CAS described in chapters 2 to 4 only require specialised software and no additional hardware. As a result, it is a relatively affordable and easy to implement technology to improve care in general clinics and it is also useful for educational and research purposes in teaching clinics. The cadaver study on the use of preoperative planning in orbital reconstruction demonstrates its important role in the workflow. Additionally, intraoperative navigation provides essential intraoperative feedback. Intraoperative control is lacking in the absence of surgical navigation. Intraoperative imaging can be used instead for the final assessment of the accuracy of the reconstruction during surgery.

**Chapter 5** demonstrates that intraoperative imaging during orbital reconstruction significantly improves the position of the implant. The surgeon is able to assess the rotations yaw and roll and adjust accordingly. Improving the translation of the implant is more difficult to accomplish. On average, the surgeon requires 1.6 CT scans to be satisfied with the final position. Intraoperative imaging has the potential to prevent revision surgery and a suboptimal position of the implant. The impact of the disadvantages (extra radiation exposure, increased operation time, and costs) should also be considered<sup>14</sup>. The extent to which these disadvantages occur could decrease with the improved quality of cone beam (CB)CT imaging. Intraoperative imaging should ideally replace postoperative imaging, so that there is no increased radiation exposure. Recent research states that routine postoperative imaging is not warranted in the absence of clinical symptoms, as it has limited added value<sup>15,16</sup>. This may be different for intraoperative imaging, given the aforementioned advantages. Besides, much can be learned from both intra- and postoperative imaging in educational and research settings.

In certain situations, preoperative planning and intraoperative CBCT imaging are the technological tools required for predictable orbital reconstruction. The preoperative plan can be used for the initial positioning of the implant and intraoperative imaging can serve as direct feedback. The position can be checked after the superimposition of the images and, if required, adjusted immediately. This approach has previously been investigated for zygomatic fractures, with or without an orbital floor fracture, with promising results<sup>17</sup>. Obtaining the best position of the implant in these types of fractures is often more complicated, compared to isolated orbital wall fractures, and might therefore benefit more from this workflow.

### **Optimisation of the treatment protocol**

The principal dilemmas in the management of orbital wall fractures are indications and timing of orbital reconstruction. Based on the clinical protocol discussed in chapter 6, an attempt was made to gain more knowledge on this subject by evaluating the results of the protocol at the end of follow-up.

Improvement of diplopia and eye motility in the first weeks after the trauma is likely to be the result of recovery after contusion, oedema, and haematoma. There is an indication for surgery if there is a limited improvement, which is presumably attributable to partial entrapment of a rectus muscle or surrounding connective tissue that needs to be explored. It is difficult to predict in the early stage how the soft tissue will recuperate. Other suspected obstacles to long-term recovery are adhesions, fibrosis, and altered anatomy of the suspension system due to disruption after trauma. Bianchi et al. state that vertical incomitance, a form of strabismus related to the acquired paralytic and mechanical-restrictive factors, could predict persistent diplopia<sup>18</sup>. According to our study, both diplopia and ductions improve significantly in the first 2 weeks, with additional substantial improvement up to 3 months. The patient-reported outcomes reveal that only a few patients experience minor limitations in the daily routine at the end of follow-up. This endorses the use of a nonsurgical approach, which also prevents iatrogenic damage.

There is conflicting evidence on the correlation between volume increase or the size of the fracture and the occurrence of enophthalmos<sup>8,19,20</sup>. Early enophthalmos is an indication for surgery and is caused by an increase in orbital volume due to a large fracture, presumably in combination with severe damage to the connective tissue (fascia sheaths, ligaments, and periorbita). Other aspects, such as fibrosis, adhesions, and posttraumatic and iatrogenic fat atrophy, might contribute more to late enophthalmos<sup>21</sup>. No significant increase of more than 2 mm enophthalmos was observed in the nonsurgical group, despite the presence of several large (>2 cm<sup>2</sup>) fractures. Late enophthalmos did not develop in both the nonsurgical and surgical groups. The hypothesis is that in large fractures without late enophthalmos, the suspension system (described by professor L. Koornneef<sup>22</sup>), is still intact and can maintain the globe approximately in the position before the trauma. As a result, fat atrophy will neither have a substantial effect on the position. The study by Young et al. supports this hypothesis<sup>23</sup>. A decrease in fracture size and orbital herniation volume after nonsurgical treatment of orbital wall fractures is observed in that study. This demonstrates the outstanding regenerative capacity of the orbital soft tissues. Merely the size of the fracture (>50 % of the surface area or >2 cm<sup>2</sup>) is not a good indication for surgery and orbital reconstruction should not be performed in anticipation of possible late enophthalmos. Indications for surgery should be based on existing rather than expected problems.

A recent systematic review by Jazayeri et al., covering all available literature on timing of surgery, illustrates that the available research is limited and of very low quality<sup>24</sup>. Although they conclude that treatment within 2 weeks results in better outcomes, there is no solid evidence to substantiate the need for early surgery. The studies had a high degree of heterogeneity. The patient characteristics, the size of the fracture, the indications for orbital reconstruction, and the rationale behind late surgery were not well defined. It is feasible that in the studies that carried out an early intervention, there was no clear indication for surgery. The favourable results are attributed to the early intervention, while these patients may have been able to cure spontaneously with a nonsurgical treatment. Patients who underwent late surgery, have already demonstrated that

they are unable to recover by themselves. The chance of these patients recovering without symptoms after surgery is poor. This may be due to a more complex fracture. The theory is that with delayed reconstruction adhesion and fibrosis complicate the reconstruction, which in turn could cause secondary trauma with possibly worse outcomes. There is insufficient and low-quality data to provide a basis for guidelines<sup>25</sup>.

The following can be concluded from the results of our study:

1. Diplopia and limited eye motility have the potential to recover after an orbital wall fracture.
2. The occurrence of late enophthalmos (>2 mm) is rare after nonsurgical treatment of large orbital wall fractures.
3. Good results are achieved with a predominantly nonsurgical approach and this is justified for most orbital wall fractures.
4. A multidisciplinary approach is beneficial to acquire more knowledge about the prevailing issues.

## Future perspectives

Computer-assisted surgery (CAS) in orbital reconstruction already ensures a high level of accuracy and predictability. Apart from substantial cost reductions, further optimisation and improved user-friendliness will enable the mainstream use of the CAS components in general clinics. Time efficiency could be improved as the automation of several components, such as automatic recognition of the fracture complexity, is possible with new promising techniques. The next step in CAS is implant-oriented navigation for better intraoperative control of complex fractures<sup>26</sup>. Augmented reality can be used for training purposes and may facilitate intraoperative highlighting of the anatomical landmarks. The combination of implant-oriented navigation and augmented reality enables the virtual projection of the planned position of the implant, eliminating the need for the surgeon to look at the multiplanar view on a computer screen<sup>27</sup>. The use of robotics is probably something for the distant future. Robotics can assist in the final positioning and stabilisation during fixation of the implant. For all technologies mentioned, it remains



important to determine whether they are cost-effective and what health gains can be achieved based on clinical outcomes.

An ongoing challenge for the future is further improvement of the clinical protocols for orbital wall fractures. There is still a blurred area for indications and timing for orbital reconstruction. Predictive values of chronic sequelae can play a key role in solving these issues<sup>19,28</sup>. More detailed analysis and understanding of the soft tissues and its response to trauma and surgery is required to determine in which cases late enophthalmos or persistent diplopia will occur. This could be realised with finite-element analysis models of orbital biomechanics. Perhaps high-resolution 7-Tesla magnetic resonance imaging can help with a detailed examination of the damaged suspension system, and the occurrence of posttraumatic fat atrophy, adhesions, and fibrosis. Based on the findings, clinical protocols can be further investigated in larger cohorts or, preferably, randomised controlled clinical trials. The management of orbital wall fractures may further be improved with the use of collective (big) data. An automated accurate prediction may become possible for various issues. For instance, to investigate the appropriate techniques for each specific fracture during orbital reconstruction, which cases should be referred to a specialised centre, or what the exact indications are for surgery.

Besides detailed objective orthoptic measurements, future orbital research should be substantiated by subjective patient-reported outcome measures (PROM), such as mood and feelings or quality-of-life questionnaires. These PROMs are so far rarely used as a primary outcome measure in orbital fractures, although they are expected to offer a clear insight into the aesthetic and functional impact of the sequelae and complications.



## References

1. Aldekhayel S, Aljaaly H, Fouda-Neel O, et al.: Evolving trends in the management of orbital floor fractures. *J Craniofac Surg* 25: 258-261, 2014
2. Hassfeld S, Mühling J, Zöllner J: Intraoperative navigation in oral and maxillofacial surgery. *Int J Oral Maxillofac Surg* 24: 111-119, 1995
3. Schreurs R, Dubois L, Becking AG, et al.: Implant-oriented navigation in orbital reconstruction. Part 1: technique and accuracy study. *Int J Oral Maxillofac Surg* 47: 395-402, 2018
4. Rana M, Holtmann H, Rana M, et al.: Primary orbital reconstruction with selective laser melted core patient-specific implants: overview of 100 patients. *Br J Oral Maxillofac Surg* 57: 782-787, 2019
5. Azarmehr I, Stokbro K, Bell B, et al.: Surgical navigation: a systematic review of indications, treatments, and outcomes in oral and maxillofacial surgery. *J Oral Maxillofac Surg* 75: 1987-2005, 2017
6. Devenci M, Oztürk S, Sengezer M, et al.: Measurement of orbital volume by a 3-dimensional software program: an experimental study. *J Oral Maxillofac Surg* 58: 645-648, 2000
7. Regensburg NI, Kok PHB, Zonneveld FW, et al.: A new and validated CT-based method for the calculation of orbital soft tissue volumes. *Invest Ophthalmol Vis Sci* 49: 1758-1762, 2008
8. Schönegg D, Wagner M, Schumann P, et al.: Correlation between increased orbital volume and enophthalmos and diplopia in patients with fractures of the orbital floor or the medial orbital wall. *J Craniomaxillofac Surg* 46: 1544-1549, 2018
9. Cuyper de B, Abeloos J, Swennen G, et al.: Intraoperative navigation and cone beam computed tomography for restoring orbital dimensions: a single-center experience. *Craniomaxillofac Trauma Reconstr*. Advanced online publication, 2020 doi:10.1177/1943387520904869
10. Friedrich RE, Bruhn M, Lohse C: Cone-beam computed tomography of the orbit and optic canal volumes. *J Craniomaxillofac Surg* 44: 1342-1349, 2016
11. Nilsson J, Nysjö J, Carlsson AP, et al.: Comparison analysis of orbital shape and volume in unilateral fractured orbits. *J Craniomaxillofac Surg* 46: 381-387, 2018
12. Tandon R, Aljadeff L, Ji S, et al.: Anatomic variability of the human orbit. *J Oral Maxillofac Surg* 78: 782-796, 2020
13. Dubois L, Schreurs R, Jansen J, et al.: Predictability in orbital reconstruction: a human cadaver study. Part II: navigation-assisted orbital reconstruction. *J Craniomaxillofac Surg* 43: 2042-2049, 2015
14. Nazimi AJ, Khoo SC, Nabil S, et al.: Intraoperative computed tomography scan for orbital fracture reconstruction. *J Craniofac Surg* 30: 2159-2162, 2019
15. Sharma AN, Tiourin E, Banyard DA, et al.: Clinical utility of postoperative computed tomography imaging in orbital floor fracture management. *Ann Plast Surg* 83: 43-47, 2019
16. Carpenter D, Shammass R, Honeybrook A, et al.: The role of postoperative imaging after orbital floor fracture repair. *Craniomaxillofac Trauma Reconstr* 11: 96-101, 2018
17. Gander T, Blumer M, Rostetter C, et al.: Intraoperative 3-dimensional cone beam computed tomographic imaging during reconstruction of the zygoma and orbit. *Oral Surg Oral Med Pathol Oral Radiol* 126: 192-197, 2018
18. Bianchi F, De Haller R, Steffen H, et al.: Does vertical incomitance predict the diplopia outcome in orbital fracture patients? A prospective study of 188 patients. *J Craniomaxillofac Surg* 47: 305-310, 2019
19. Choi SH, Kang DH: Prediction of late enophthalmos using preoperative orbital volume and fracture area measurements in blowout fracture. *J Craniofac Surg* 28: 1717-1720, 2017
20. Gabrick K, Smetona J, Iyengar R, et al.: Radiographic predictors of FACE-Q outcomes following non-operative orbital floor fracture management. *J Craniofac Surg*. Advanced online publication, 2020 doi:10.1097/SCS.0000000000006356
21. Snäll J, Narjus-Sterba M, Toivari M, et al.: Does postoperative orbital volume predict postoperative globe malposition after blow-out fracture reconstruction? A 6-month clinical follow-up study. *Oral Maxillofac Surg* 23: 27-34, 2019

22. Koornneef L: New insights in the human orbital connective tissue: result of a new anatomical approach. *Arch Ophthalmol* 95: 1269-1273, 1977
23. Young SM, Kim YD, Kim SW, et al.: Conservatively treated orbital blowout fractures. *Ophthalmology* 125: 938-944, 2018
24. Jazayeri HE, Khavanin N, Yu JW, et al.: Does early repair of orbital fractures result in superior patient outcomes? A systematic review and meta-analysis. *J Oral Maxillofac Surg* 78: 568-577, 2020
25. Dubois L, Steenen SA, Gooris PJJ, et al.: Controversies in orbital reconstruction - II. Timing of post-traumatic orbital reconstruction: a systematic review. *Int J Oral Maxillofac Surg* 44: 433-440, 2015
26. Schreurs R, Dubois L, Ho JPTF, et al.: Implant-oriented navigation in orbital reconstruction part II: preclinical cadaver study. *Int J Oral Maxillofac Surg* 49: 678-685, 2020
27. Ayoub A, Pulijala Y: The application of virtual reality and augmented reality oral & maxillofacial surgery. *BMC Oral Health* 19: 238, 2019
28. Zimmerer RM, Gellrich NC, von Bülow S, et al.: Is there more to the clinical outcome in posttraumatic reconstruction of the inferior and medial orbital walls than accuracy of implant placement and implant surface contouring? A prospective multicenter study to identify predictors of clinical outcome. *J Craniomaxillofacial Surg* 46: 578-587, 2018



C  
H  
A  
P  
T  
E  
R

8

Summary in  
English and Dutch



## Summary

This PhD thesis provides detailed insight into several components of computer-assisted orbital reconstruction and contributes to the improvement of orbital wall fracture management. Technology fulfills an important role in the current treatment of these fractures. A substantial amount of research is required to prove the effectiveness of newly developed technological aids. While technological developments are rapidly evolving, there is still a lack of consensus on certain aspects of treatment. Many decades ago, two opposing treatment strategies emerged: the predominantly nonsurgical approach and the early surgical approach. There is no generally accepted treatment protocol.

Several topics are introduced in chapter 1 to illustrate why there is a necessity for technological tools and clear treatment protocols. The topics discussed are anatomy, trauma mechanism, surgical principles (surgical approach, anatomical landmarks, and implant material), technological developments, and the management of orbital fractures.

The orbital anatomy is complex. The orbital cavity is compact, has a conical shape, and the orbital floor and medial wall are thin and fragile. The soft tissue consists of neurovascular structures, adipose tissue, connective tissue, muscles, and the globe. These are all delicate structures and especially the connective tissue has an intricate architecture with fascia sheaths, septa, ligaments, and the periorbita, that function as a suspension system. Trauma often involves a fracture of the floor and medial wall and it is very important to which extent the suspension system is affected.

A clear overview is important during orbital reconstruction because of the complex anatomy. This can be achieved with an adequate surgical approach, such as the transconjunctival approach. Surgical guidance is obtained by the identification of multiple anatomical landmarks. Besides a sound overview during surgery, the success of the reconstruction is also based on the implant used. A titanium implant is considered the gold standard, as it adheres best to the demands of surgery. To further facilitate the surgeon, technological aids have been implemented in



the workflow. Computer-assisted surgery (CAS) consists of several preoperative, intraoperative, and postoperative components. Virtual three-dimensional (3D) diagnostics and preoperative planning include volume measurement, mirroring of the unaffected side onto the affected side, and virtual surgery to select the ideal implant. Intraoperative control is achieved with navigation and computed tomography (CT) imaging. The position of the implant can also be evaluated after surgery during postoperative analysis.

The most important consequences of orbital wall fractures are persistent diplopia and enophthalmos. There is no uniform treatment strategy for large fractures with initially severe diplopia and without early enophthalmos. The main discussion revolves around indications and timing of surgery. Proponents of a predominantly nonsurgical approach point to the regenerative capacity of the body to resolve diplopia and the rare development of late enophthalmos. Proponents of early surgical intervention propagate that it has better outcome and causes less iatrogenic damage.

The specific aims of this PhD thesis are:

1. To investigate the added value of relevant individual diagnostic, preoperative, and intraoperative components of computer-assisted orbital reconstruction.
2. To improve the management of orbital wall fractures by assessing the implementation of an updated clinical protocol with special emphasis on functional outcome.

One of the first components in the workup of CAS is measurement of the increased orbital volume after an orbital fracture, as it can be useful in assessing the severity of the fracture. Chapter 2 describes three (semi-) automatic software segmentation methods to measure orbital volume in the unaffected bony orbit. Based on 21 CT scans, one unaffected orbit per scan is used to compare the gold standard, manual segmentation, with the three methods: method A (automatic), method SA (automatic minus bone and air masks), and method SAA (automatic minus both masks followed by manual adjustments). It can be concluded that method A is



quick, but not accurate enough. Method SA has the best combination of time efficiency (mean 146 seconds, SD 16), accuracy (mean 0.24 cc, SD 0.27), perfect reproducibility, and ease of use. Although method SAA is more time-consuming and less accurate, it does show better potential in measuring increased orbital volume after orbital wall fracture, due to the ability to manually adjust. The method is not yet validated for this purpose.

In **chapter 3**, volume and contour differences between unaffected orbital cavities are measured using method SA. Mirroring is an important step in diagnostics and virtual preoperative planning and relies on the assumed symmetry of the orbital walls. The measurements are performed on the CT scans of 100 patients without orbital pathology. The mean difference between both orbital cavities is 0.44 cc (SD 0.31) or 1.59 % (SD 1.10 %). There is also a high similarity in orbital contour with an absolute mean difference of 0.82 mm (SD 0.23). These differences are clinically insignificant and will not lead to fundamental errors in planning the orbital reconstruction. The mirroring technique is therefore considered very useful to plan the best-fit position of the implant prior to orbital reconstruction.

Advanced 3D diagnostics and preoperative planning ensure optimal preparation for the surgeon. During the virtual surgery, assessment of the fracture, the anatomical landmarks, the implant size, and the best position of the implant is possible. In the complete workflow of CAS, intraoperative navigation is used for real-time feedback during the orbital reconstruction. **Chapter 4** demonstrates that the use of preoperative virtual planning, without intraoperative navigation, improves the position of the implant. In this study, orbital reconstruction is performed on ten cadavers with intentionally created, complex, orbital wall fractures. The surgeon can consult the preoperative plan and the CT scan on a screen in the operating theatre. The actual implant position is compared to the ideal implant position. Translation and the rotations yaw and roll improve significantly ( $p < 0.05$ ). The preoperative plan can be considered the most important step in CAS. Another benefit of preoperative planning is that it enables postoperative analysis.



In chapter 5, the effects of intraoperative CT imaging in orbital reconstruction are discussed. It enables the surgeon to check and adjust the position of the implant during surgery. The same ten cadavers from the aforementioned cadaver study are used. A CT scan is acquired during the reconstruction and the implant is adjusted if necessary. The CT scans are repeated until the surgeon is satisfied. The position of the implant is compared to the ideal position and yaw and roll improve significantly ( $p < 0.05$ ). On average, 1.6 scans are required to achieve the desired result and the main reason for alteration is the rotation roll. The significant improvement in the position of the implant and the possible prevention of revision surgery could outweigh the disadvantages, which include extra radiation exposure, increased operation time, and added costs.

The management of orbital fractures is still open for discussion as there is no widely accepted clinical protocol. The results of an updated clinical protocol for orbital wall fractures are presented in chapter 6. The emphasis is placed on nonsurgical treatment, frequent orthoptic measurements, and a multidisciplinary approach. In the prospective cohort study, patients underwent clinical assessment and orthoptic evaluation up to 12 months after trauma or surgery. Most patients (46 out of 58) received nonsurgical treatment. Results demonstrated that 45 out of all 58 patients had an excellent outcome and the other patients had limited diplopia. The average quality-of-life score at the end of follow-up was 97 out of 100. Late enophthalmos did not develop in any of the patients. Based on these results, it can be stated that the body has a good regenerative capacity and that most orbital wall fractures benefit from a nonsurgical approach with adequate orthoptic evaluation.

In chapter 7, all findings are combined and evaluated in the general discussion and a perspective for the future is provided. All diagnostic and preoperative components of CAS are available with solely specialised software. The results of this thesis indicate substantial added value of virtual diagnostics and preoperative planning using 3D software. These tools are relatively easy to use and affordable to implement in general clinics. They improve clinical care and can be used for teaching and research purposes. The combination of virtual preoperative planning and

intraoperative CT imaging may prove to be valuable. In the management of orbital wall fractures, it is important to avoid early intervention. Diplopia and eye motility recover substantially in the first 2 weeks to 3 months and it is unnecessary to perform surgery to avoid expected enophthalmos. There is no conclusive evidence that early surgery within 2 weeks improves clinical outcome.

The future of CAS in orbital reconstruction is further optimisation and improved user-friendliness for mainstream use in general clinics. The next step in CAS is implant-oriented navigation. Augmented reality and robotics are other technological advancements to assist the surgeon in the future. Furthermore, the management of orbital wall fractures could be improved by analysing the posttraumatic soft tissue and the regenerative capacity. In addition to clinical objective outcomes, cost-effectiveness, and patient-reported subjective outcomes should be further investigated.





## Nederlandse samenvatting

Dit proefschrift geeft een gedetailleerd inzicht in verschillende onderdelen van computer-geassisteerde reconstructie van de orbita en draagt bij aan de verbetering van de behandeling van orbita fracturen. Technologie vervult een belangrijke rol in de huidige behandeling van deze fracturen. Er is veel onderzoek nodig om de effectiviteit van nieuw ontwikkelde technologische hulpmiddelen aan te tonen. Terwijl technologische ontwikkelingen zich snel ontwikkelen, is er nog geen duidelijke consensus of en wanneer een patiënt met een orbita fractuur een operatieve behandeling zou moeten ondergaan. Vele decennia geleden ontstonden er twee tegengestelde behandelstrategieën: de overwegend niet-chirurgische aanpak en de vroege chirurgische aanpak. Er is tot op heden nog geen algemeen aanvaard behandelprotocol.

In hoofdstuk 1 worden verschillende onderwerpen geïntroduceerd om uit te leggen waarom er behoefte is aan technologische hulpmiddelen en duidelijke behandelprotocollen. De besproken onderwerpen zijn anatomie, trauma mechanisme, chirurgische principes (chirurgische benadering, anatomische oriëntatiepunten en het implantaat materiaal), technologische ontwikkelingen en het management van orbita fracturen.

De anatomie van de orbita is complex, compact en heeft een conische vorm. De bodem en mediale wand van de orbita zijn dun en kwetsbaar. De weke delen bestaan uit neurovasculaire structuren, vetweefsel, bindweefsel, spieren en de oogbol. Dit zijn allen delicate structuren en vooral het bindweefsel heeft een ingewikkelde architectuur met fascia, septa, ligamenten en de periorbita die functioneren als een ophangstelsel. Bij een trauma is vaak de bodem en mediale wand van de orbita aangedaan. Daarnaast is het relevant in hoeverre het ophangstelsel is aangetast.

Het is belangrijk om voldoende overzicht te hebben tijdens de reconstructie van de orbita vanwege de complexe anatomie. Dit kan worden bereikt door een goede chirurgische benadering, zoals de transconjunctivale benadering. Het overzicht voor de chirurg kan verder verbeterd worden

door de identificatie van meerdere anatomische oriëntatiepunten. Naast voldoende overzicht tijdens de operatie, is het succes van de reconstructie tevens gebaseerd op het gebruikte implantaat materiaal. Een titanium implantaat wordt beschouwd als de gouden standaard, omdat deze het beste voldoet aan de gestelde chirurgische eisen. Om de chirurg verder te faciliteren zijn er technologische hulpmiddelen geïmplementeerd in het werkproces. Computer-geassisteerde chirurgie bestaat uit verschillende preoperatieve, intraoperatieve en postoperatieve componenten. De virtuele driedimensionale (3D) diagnostiek en preoperatieve planning omvat de volumemeting van de orbita, het spiegelen van de niet-aangedane zijde over de aangedane zijde en virtuele chirurgie om het ideale implantaat te selecteren. Intraoperatieve controle wordt bereikt met behulp van navigatie en computertomografie (CT). De positie van het implantaat kan ook na de operatie, tijdens de postoperatieve analyse, worden gecontroleerd.

De belangrijkste gevolgen van orbita fracturen zijn persisterende diplopie en enophthalmus. Vooral bij de behandeling van grote fracturen, met initieel ernstige diplopie en geen vroegtijdige enophthalmus, is er geen uniforme behandelstrategie. Bij de behandeling van deze fracturen gaat het vooral om de indicaties en de timing van de operatie. Voorstanders van een overwegend niet-chirurgische aanpak wijzen op het regeneratieve vermogen van het lichaam om diplopie op te lossen en de beperkte ontwikkeling van late enophthalmus. Voorstanders van een vroege chirurgische ingreep propageren een beter resultaat en minder iatrogene schade.

De specifieke doelstellingen van dit proefschrift zijn:

1. Het onderzoeken van de toegevoegde waarde van relevante individuele diagnostische, preoperatieve en intraoperatieve componenten van computer-geassisteerde reconstructie van de orbita.
2. De behandeling van orbita fracturen verbeteren door de implementatie van een nieuw klinisch protocol met speciale nadruk op de functionele uitkomst.

Eén van de eerste onderdelen van computer-geassisteerde chirurgie is het meten van het toegenomen volume van de benige orbita na een orbita fractuur, omdat dit nuttig kan zijn bij het beoordelen van de ernst van de fractuur. In hoofdstuk 2 worden drie (semi-)automatische segmentatie methoden beschreven om het volume van een onaangetaste orbita te meten met behulp van gespecialiseerde software. Bij 21 patiënten wordt op basis van de CT-scan één onaangetaste orbita gebruikt om de gouden standaard, handmatige segmentatie, te vergelijken met de drie methoden: methode A (automatisch), methode SA (automatisch minus bot- en luchtmaskers) en methode SAA (automatisch minus beide maskers, gevolgd door handmatige aanpassingen). Er kan worden geconcludeerd dat methode A snel is, maar niet de meest nauwkeurige. Methode SA heeft de beste combinatie van tijdsefficiëntie (gemiddeld 146 seconden, SD 16), nauwkeurigheid (gemiddeld 0,24 cc, SD 0,27), perfecte reproduceerbaarheid en gebruiksgemak. Hoewel methode SAA meer tijdrovend en minder nauwkeurig is, geeft het wel een beter perspectief om het toegenomen volume na een orbita fractuur te meten, omdat het mogelijk is om handmatig aanpassingen te doen. De methode is echter nog niet gevalideerd voor dit doel.

In hoofdstuk 3 worden de volume- en contourverschillen tussen onaangedane orbita's gemeten met methode SA. Spiegelen is een belangrijke stap bij de diagnostiek en virtuele preoperatieve planning en berust op de veronderstelde symmetrie van de wanden van de orbita. De metingen worden uitgevoerd op de CT-scan van 100 patiënten zonder pathologie van de orbita. Het gemiddelde verschil tussen de orbita's is 0,44 cc (SD 0,31) of 1,59 % (SD 1,10 %). Er is ook een grote overeenkomst in de contour van de orbita met een absoluut gemiddeld verschil van 0,82 mm (SD 0,23). Deze verschillen zijn klinisch onbelangrijk en zullen niet leiden tot fundamentele fouten tijdens de planning. De spiegeltechniek wordt daarom als zeer nuttig beschouwd om de beste positie van het implantaat voorafgaand aan de orbita reconstructie te bepalen.

Geavanceerde 3D diagnostiek en preoperatieve planning zorgen voor een optimale voorbereiding voor de chirurg. Tijdens de virtuele chirurgie is beoordeling van de fractuur, de anatomische oriëntatiepunten, de



grootte en de beste positie van het implantaat mogelijk. In de volledige workflow van computer-geassisteerde chirurgie wordt intraoperatieve navigatie gebruikt voor real-time feedback tijdens de orbita reconstructie. Hoofdstuk 4 laat zien dat het gebruik van preoperatieve virtuele planning, zonder intraoperatieve navigatie, de positie van het implantaat verbetert. In dit onderzoek wordt de reconstructie van de orbita uitgevoerd bij tien kadavers met opzettelijk gecreëerde, complexe, orbita fracturen. De chirurg kan het preoperatieve plan en de CT-scan raadplegen op een scherm in de operatiekamer. De werkelijke positie van het implantaat wordt vergeleken met de ideale positie van het implantaat. De translatie en de rotaties yaw en roll verbeteren significant ( $p < 0,05$ ). Het preoperatieve plan kan worden beschouwd als de belangrijkste stap in computer-geassisteerde chirurgie, die eventueel kan worden aangevuld met real-time feedback van intraoperatieve navigatie. Een ander voordeel van preoperatieve planning is dat het postoperatieve analyse mogelijk maakt.

In hoofdstuk 5 worden de effecten van intraoperatieve CT-beeldvorming bij de reconstructie van de orbita besproken. Het stelt de chirurg in staat om de positie van het implantaat tijdens de operatie te controleren en zonodig aan te passen. Dezelfde tien kadavers uit het andere kadaveronderzoek zijn gebruikt. Tijdens de reconstructie wordt een CT-scan gemaakt en wordt de positie van het implantaat zo nodig aangepast. De CT-scans worden herhaald totdat de chirurg tevreden is. De positie van het implantaat wordt vergeleken met de ideale positie en yaw en roll blijken significant te verbeteren ( $p < 0,05$ ). Gemiddeld zijn er 1,6 scans nodig totdat het resultaat naar tevredenheid is en de belangrijkste reden voor de wijziging is de rotatie roll. De significante verbetering van de positie van het implantaat en het eventueel voorkomen van een revisieoperatie wegen waarschijnlijk op tegen de nadelen, zoals extra blootstelling aan straling, langere operatieduur en aanvullende kosten.

Er is nog altijd discussie over de behandeling van orbita fracturen, omdat er geen algemeen geaccepteerd klinisch protocol is. De resultaten van een nieuw klinisch protocol voor orbita fracturen worden in hoofdstuk 6 gepresenteerd. De nadruk ligt op niet-chirurgische behandeling, frequente orthoptische metingen en een multidisciplinaire aanpak. In de



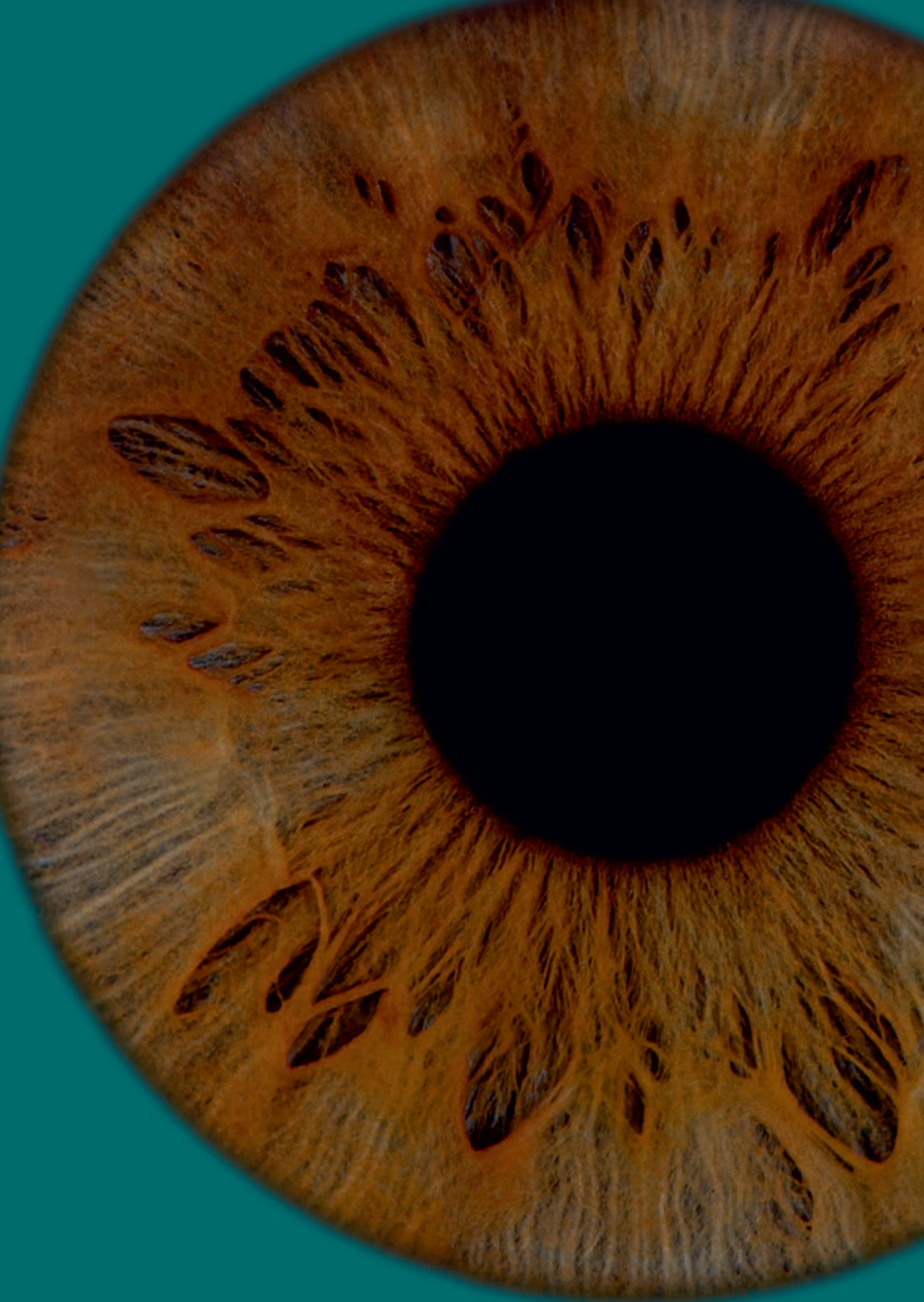prospectieve cohortstudie kregen patiënten een klinische beoordeling en een orthoptische evaluatie tot 12 maanden na het trauma of de operatie. De meeste patiënten (46 van de 58) kregen een niet-chirurgische behandeling. Bij 45 van de 58 patiënten was er een uitstekend resultaat en de overige patiënten hadden een beperkte mate van diplopie. De gemiddelde score voor kwaliteit van leven aan het einde van de follow-up was 97 van de 100 punten. Late enophthalmus ontwikkelde zich bij geen van de patiënten. Op basis van deze resultaten kan worden gesteld dat het lichaam een goed regeneratief vermogen heeft en dat de meeste orbita fracturen baat hebben bij een niet-chirurgische aanpak met een adequate orthoptische evaluatie.

In hoofdstuk 7 worden alle bevindingen gecombineerd en geëvalueerd in de algemene discussie en wordt een toekomstperspectief geboden. Voor het gebruik van de diagnostische en preoperatieve componenten van computer-geassisteerde chirurgie voor orbita reconstructies is alleen gespecialiseerde software nodig. De resultaten van dit proefschrift wijzen op een grote toegevoegde waarde van deze software. De software is relatief eenvoudig en betaalbaar, waardoor het de implementatie in algemene klinieken mogelijk maakt. Het gebruik van enkel de software voor analyse verbetert de klinische zorg en kan tevens worden gebruikt voor onderwijs- en onderzoeksdoeleinden. De combinatie van virtuele preoperatieve planning en intraoperatieve CT-beeldvorming kan een waardevolle combinatie zijn. Op basis van het beschreven behandelprotocol voor de behandeling van orbita fracturen blijkt dat het belangrijk is om vroegtijdig ingrijpen te voorkomen. Diplopie en oogmotiliteit herstellen aanzienlijk in de eerste 2 weken tot 3 maanden en het is onnodig om een operatie uit te voeren om mogelijk te verwachten enophthalmus te vermijden. Er is geen sluitend bewijs dat een operatie binnen 2 weken het klinische resultaat verbetert.

De toekomst van computer-geassisteerde chirurgie bij reconstructies van de orbita ligt in verdere optimalisatie en verbeterde gebruiksvriendelijkheid voor meer algemeen gebruik in klinieken. De volgende stap in computer-geassisteerde chirurgie is implantaat-georiënteerde navigatie. Augmented reality en robotica zijn andere technologische ontwikkelingen om de

chirurg in de toekomst te assisteren. Daarnaast kan de behandeling van orbita fractures worden verbeterd door meer te weten te komen over de weke delen na trauma en het regeneratievermogen. Naast de klinische objectieve uitkomst is het noodzakelijk dat er ook meer onderzoek komt naar kosteneffectiviteit en de patiënt-gerapporteerde subjectieve uitkomst van de behandeling.







# Appendices

# List of contributing authors

**A.G. Becking (AB)**

Department of Oral and Maxillofacial Surgery  
Amsterdam UMC location AMC  
University of Amsterdam,  
the Netherlands

**L.F. Beenen (LB)**

Department of Radiology  
Amsterdam UMC location AMC  
University of Amsterdam,  
the Netherlands

**L. Dubois (LD)**

Department of Oral and Maxillofacial Surgery  
Amsterdam UMC location AMC  
University of Amsterdam,  
the Netherlands

**P.J.J. Gooris (PG)**

Department of Oral and Maxillofacial Surgery  
Amsterdam UMC location AMC  
University of Amsterdam,  
the Netherlands

**L.J.C. Hartman (LH)**

Department of Ophthalmology  
Amphia hospital Breda,  
the Netherlands

**J. Jansen (JJ)**

Department of Oral and Maxillofacial Surgery  
Amsterdam UMC location AMC  
University of Amsterdam,  
the Netherlands

**H.M. Jellema (HJ)**

Department of Ophthalmology  
Amsterdam UMC location AMC  
University of Amsterdam,  
the Netherlands

**J. de Lange (JL)**

Department of Oral and Maxillofacial Surgery  
Amsterdam UMC location AMC  
University of Amsterdam,  
the Netherlands

**T.J.J. Maal (TM)**

3D Lab of Oral and Maxillofacial Surgery  
Amsterdam UMC location AMC  
University of Amsterdam,  
the Netherlands

**M.P. Mourits (MM)**

Department of Ophthalmology  
Amsterdam UMC location AMC  
University of Amsterdam,  
the Netherlands

**P. Neomagus PN)**

Department of Ophthalmology  
Amphia hospital Breda,  
the Netherlands

**R. Schreurs (RS)**

3D Lab of Oral and Maxillofacial Surgery  
Amsterdam UMC location AMC  
University of Amsterdam,  
the Netherlands



## Chapter 2

*Published as:*

### **Orbital volume analysis: validation of a semi-automatic software segmentation method**

*Authors:*

J. Jansen, R. Schreurs, L. Dubois, T.J.J. Maal, P.J.J. Gooris, A.G. Becking

*Published in:*

International Journal of Computer Assisted Radiology and Surgery, 2016

*Author contributions:*

Conceived and designed the study: JJ, RS, LD, TM, AB

Performed the study: JJ, RS

Analysed the data: JJ, RS, TM

Critically revised the manuscript: JJ, RS, LD, TM, PG, AB

## Chapter 3

*Published as:*

### **Should virtual mirroring be used in the preoperative planning of an orbital reconstruction?**

*Authors:*

J. Jansen, L. Dubois, R. Schreurs, P.J.J. Gooris, T.J.J. Maal, L.F. Beenen, A.G. Becking

*Published in:*

Journal of Oral and Maxillofacial Surgery, 2018

*Author contributions:*

Conceived and designed the study: JJ, LD, RS, TM, AB

Performed the study: JJ, LB

Analysed the data: JJ, LD, RS, TM

Critically revised the manuscript: JJ, LD, RS, PG, TM, LB, AB



## Chapter 4

*Published as:*

**The advantages of advanced computer-assisted diagnostics and three-dimensional preoperative planning on implant position in orbital reconstruction**

*Authors:*

J. Jansen, R. Schreurs, L. Dubois, T.J.J. Maal, P.J.J. Gooris, A.G. Becking

*Published in:*

Journal of Cranio-Maxillofacial Surgery, 2018

*Author contributions:*

Conceived and designed the study: JJ, RS, LD, TM, PG, AB

Performed the study: LD, PG

Analysed the data: JJ, RS, LD, TM

Critically revised the manuscript: JJ, RS, LD, TM, PG, AB

## Chapter 5

*Published as:*

**Intraoperative imaging in orbital reconstruction: how does it affect implant position?**

*Authors:*

J. Jansen, R. Schreurs, L. Dubois, T.J.J. Maal, P.J.J. Gooris, A.G. Becking

*Published in:*

British Journal of Oral and Maxillofacial Surgery, 2020

*Author contributions:*

Conceived and designed the study: JJ, RS, LD, TM, PG, AB

Performed the study: LD, PG

Analysed the data: JJ, RS, LD, TM

Critically revised the manuscript: JJ, RS, LD, TM, PG, AB



## Chapter 6

*Published as:*

**A nonsurgical approach with repeated orthoptic evaluation is justified for most blow-out fractures**

*Authors:*

J. Jansen, L. Dubois, T.J.J. Maal, M.P. Mourits, H.M. Jellema, P. Neomagus, J. de Lange, L.J.C. Hartman, P.J.J. Gooris, A.G. Becking

*Published in:*

Journal of Cranio-Maxillofacial Surgery, 2020

*Author contributions:*

Conceived and designed the study: JJ, LD, TM, MM, HJ, PG, AB

Performed the study: JJ, LD, HM, PN, LH, PG

Analysed the data: JJ, LD, MP

Critically revised the manuscript: JJ, LD, TM, MM, HJ, JL, PG, AB

# List of publications

Peer reviewed full-text publications

### **In this thesis**

Orbital volume analysis: validation of a semi-automatic software segmentation method

J. Jansen, R. Schreurs, L. Dubois, T.J.J. Maal, P.J.J. Gooris, A.G. Becking  
*Int J Comput Assist Radiol Surg* 11: 11-18, 2016

Should virtual mirroring be used in the preoperative planning of an orbital reconstruction?

J. Jansen, L. Dubois, R. Schreurs, P.J.J. Gooris, T.J.J. Maal, L.F. Beenen, A.G. Becking  
*J Oral Maxillofac Surg* 76: 380-387, 2018

The advantages of advanced computer-assisted diagnostics and three-dimensional preoperative planning on implant position in orbital reconstruction

J. Jansen, R. Schreurs, L. Dubois, T.J.J. Maal, P.J.J. Gooris, A.G. Becking  
*J Craniomaxillofac Surg* 46: 715-721, 2018

Intraoperative imaging in orbital reconstruction: how does it affect implant position?

J. Jansen, R. Schreurs, L. Dubois, T.J.J. Maal, P.J.J. Gooris, A.G. Becking  
*Br J Oral Maxillofac Surg* 58: 801-806, 2020

A nonsurgical approach with repeated orthoptic evaluation is justified for most blow-out fractures

J. Jansen, L. Dubois, T.J.J. Maal, M.P. Mourits, H.M. Jellema, P. Neomagus, J. de Lange, L.J.C. Hartman, P.J.J. Gooris, A.G. Becking  
*J Craniomaxillofac Surg* 48: 560-568, 2020

## Other

Predictability in orbital reconstruction: A human cadaver study. Part I: Endoscopic-assisted orbital reconstruction  
L. Dubois, J. Jansen, R. Schreurs, P. Saeed, L. Beenen, T.J.J. Maal, P.J.J. Gooris, A.G. Becking  
*J Craniomaxillofac Surg* 43: 2034-2041, 2015

Predictability in orbital reconstruction: A human cadaver study. Part II: Navigation-assisted orbital reconstruction  
L. Dubois, R. Schreurs, J. Jansen, T.J.J. Maal, H. Essig, P.J.J. Gooris, A.G. Becking  
*J Craniomaxillofac Surg* 43: 2042-2049, 2015

Predictability in orbital reconstruction. A human cadaver study, part III: Implant-oriented navigation for optimized reconstruction  
L. Dubois, H. Essig, R. Schreurs, J. Jansen, T.J.J. Maal, P.J.J. Gooris, A.G. Becking  
*J Craniomaxillofac Surg* 43: 2050-2056, 2015

How reliable is the visual appraisal of a surgeon for diagnosing orbital fractures?  
L. Dubois, J. Jansen, R. Schreurs, P.E. Habets, S.M. Reinartz, P.J.J. Gooris, A.G. Becking  
*J Craniomaxillofac Surg* 44: 1015-1024, 2016

Acute respiratory distress in a frail older patient: spontaneous tooth aspiration  
J. Jansen, C.D. van der Maarel-Wierink, L. Dubois  
*Ned Tijdschr Tandheelkd* 127: 282-285, 2020



# PhD portfolio

## PhD portfolio

Name PhD student: Jesper Jansen  
 PhD period: September 2013 - October 2020  
 PhD supervisor: professor A.G. Becking

Courses	Year	ECTS
Embase/medline - Graduate School Academic Medical Center	2014	1
Endnote - Graduate School Academic Medical Center	2014	1
Biostatistics - Graduate School Academic Medical Center	2014	3
Basic course in legislation and organisation for clinical researchers (BROK)- Academic Medical Center	2014	2
Scientific writing in English - Graduate School Academic Medical Center	2015	4
Scientific integrity - Academic Center for Dentistry Amsterdam	2016	2
BROK re-registration	2018	1
(Inter)national conferences	Year	ECTS
Najaarsvergadering NVMKA, Bussum, The Netherlands	2014	1
Computer Assisted Radiology and Surgery (CARS) Congress, Barcelona, Spain	2015	1,5
97 <sup>th</sup> Congress of the American Association of Oral and Maxillofacial Surgery, Washington, USA	2015	1,5
Najaarsvergadering NVMKA, Amersfoort, The Netherlands	2015	1
23 <sup>th</sup> Congress of the European Association for Cranio Maxillo Facial Surgery, London, UK	2016	1,5
Najaarsvergadering NVMKA, Scheveningen, The Netherlands	2017	1
Oral presentations	Year	ECTS
Orbital volume analysis: validation of a semi-automatic software segmentation method <i>Najaarsvergadering NVMKA, Bussum, The Netherlands</i>	2014	0,5
Orbital volume analysis: validation of a semi-automatic software segmentation method <i>Computer Assisted Radiology and Surgery Congress, Barcelona, Spain</i>	2015	0,5
Transconjunctival versus endoscopic assisted orbital reconstruction: a human cadaver study on the predictability of implant position <i>97<sup>th</sup> Congress of the American Association of Oral and Maxillofacial Surgery, Washington, USA</i>	2015	0,5
Kan het gebruik van een endoscoop een steentje bijdragen aan de voorspelbaarheid van orbita reconstructies? <i>Najaarsvergadering NVMKA, Amersfoort, The Netherlands</i>	2015	0,5
The effects of 3D preoperative planning on implant position in orbital reconstruction: a human cadaver study <i>23<sup>th</sup> Congress of the European Association for Cranio Maxillo Facial Surgery, London, UK</i>	2016	0,5
Is a wait-and-see policy justified for orbital wall fractures? A multidisciplinary prospective observational study <i>Najaarsvergadering NVMKA, Scheveningen, The Netherlands</i>	2017	0,5
Guidance and training	Year	ECTS
Guidance and training by the supervisors	2014-2020	6
<b>Total ECTS</b>		<b>30,5</b>



# Acknowledgements / Dankwoord



Tijdens een promotietraject ligt er maar één stip aan de horizon: de dag waarop je het proefschrift mag verdedigen. Maar eerst is het tijd om even stil te staan en terug te kijken. Ten tijde van de COVID-19 epidemie beseft iedereen hoe welkom dat eigenlijk is. Fulltime promoveren was voor mij geen optie, maar promoveren in de late uurtjes, weekenden en vakanties heeft het uiterste van mij en mijn omgeving gevegd gedurende een lange periode. Ik ben uitermate dankbaar voor de hulp die ik op vele fronten heb mogen ontvangen van collega's, familie en vrienden, zowel voor de inspanning als de ontspanning, en ben trots op het eindresultaat dat hier nu ligt. Zonder hen was het voltooien van dit proefschrift een onmogelijke opgave geweest.

Prof. dr. A.G. Becking, hooggeleerde promotor, beste Eddy, ik vind het een voorrecht dat ik de afgelopen jaren zoveel begeleiding en wijze lessen van je heb mogen ontvangen. Het is geen toeval dat het orbitateam direct een schot in de roos was. Een groep met verschillende persoonlijkheden en capaciteiten, maar toch met een goede klik onder jouw aanvoering met veel persoonlijke aandacht. Ondanks een volle agenda zorgde je voor structuur met vergaderingen en voor ontspanning en binding met etentjes. Diep respect hoe je de academie, periferie en bovenal een rijk privéleven met een mooi gezin kan combineren. En uiteraard ook nog tijd kan vinden om af en toe te golfen. Ook veel dank voor de kennis en ervaring die ik op heb mogen doen in Haarlem als ANIOS. Een prachtige, vooruitstrevende en leuke maatschap.

Prof. dr. T.J.J. Maal, hooggeleerde promotor, beste Thomas, mijn eerste wetenschappelijke stappen werden gezet op jouw thuisbasis: het 3D lab in Nijmegen. Een hele week CT-scans handmatig segmenteren slice voor slice; wat een werk. In Amsterdam heb je samen met Eddy de basis gelegd voor een succesvolle onderzoeksgroep. Je positieve instelling en werklust werken aanstekelijk en zonder jouw specifieke technische kennis was dit proefschrift er niet geweest. Ik ben trots dat ik veel heb mogen leren van de eerste hoogleraar 3D technologie in de gezondheidszorg en hoop in de toekomst nog vaak met je samen te werken.



Dr. P.J.J. Gooris, zeergeleerde copromotor, beste Peter, als rode draad door mijn promotietraject liep de 'OFC studie'; hoofdstuk 6 in dit proefschrift. In Amsterdam en bij jou in het Amphia ziekenhuis in Breda hebben we de nodige uren gewerkt aan het nalopen van de geïncludeerde patiënten. Zoals het een Brabander betaamt, ben je zeer gastvrij. Dit uitte zich in de worstenbroodjes, lekkere espresso's en een goed glas wijn in de achtertuin met uitkijk op het Montensbos. Toen ik belde voor restaurant tips in Breda, omdat ik met vrienden in de buurt ging mountainbiken, kreeg ik niet alleen tips voor restaurants, maar ook de sleutel van je huis om daar te overnachten. Een onmisbare en stabiele schakel in de onderzoeksgroep.

Dr. L. Dubois, zeergeleerde copromotor, beste Leander, Don Leo, onze eerste kennismaking was voorafgaand aan mijn wetenschappelijke stage op maandag 31 oktober 2011. Ik heb het aan jou en Eddy te danken dat ik aan mijn promotietraject kon beginnen. Ik vond het een eer dat ik in 2016 je paranimf mocht zijn en ik weet zeker dat ik tijdens mijn opleiding nog veel van je ga leren. Op de werkvloer, thuis met het gezin, tijdens het sporten of aan de bar, je bent niet te stoppen en gaat overal maximaal voor. Living life to the fullest. We hebben vaak tot laat in de avond met Ruud staan filosoferen over onderzoek en de toekomst. Ik ben benieuwd hoe die er voor ons allen uitziet. Laten we de avonden varen er in ieder geval in houden!

Prof. dr. Jan de Lange, hooggeleerde heer, beste Jan, de sollicitatieronde tijdens mijn wetenschappelijke stage in 2012 kwam iets te vroeg, maar gelukkig heb ik in de jaren daarna toch een opleidingsplek kunnen bemachtigen. U staat aan de basis van de huidige afdeling en ik kan mij geen beter en veiliger opleidingsklimaat bedenken: open, zelfstandig, gedreven en betrokken. Ik zal niet snel vergeten dat ik in mijn eerste maanden van de opleiding de opleider uit een belangrijke vergadering moest halen, omdat ik de 48 er niet uit kreeg en er verder geen stafleden beschikbaar waren. Daar staat uiteraard wel tegenover dat ik graag kom helpen als de accu van de Alfa Romeo weer eens leeg is.

Geachte overige leden van de promotiecommissie, prof. dr. F.R. Rozema, prof. dr. M.P. Mourits, prof. dr. H.S. Tan, dr. M.L.L. de Win en dr. B. van

Minnen. Dank voor het kritisch beoordelen van dit proefschrift. Het is een eer om mijn proefschrift tegenover u allen te verdedigen tijdens het laatste uur van mijn promotietraject.

Beste paranimfen, Ruud en Ron, ik kan me geen beter team wensen met wie ik de laatste beproeving van mijn promotietraject zal doorstaan.

Ruud, we hebben de afgelopen jaren veel samengewerkt en ik heb vaak bij je aangeklopt als het voor mij te moeilijk werd, ondanks dat de muziek die op stond elk jaar slechter werd. Samen met Niels ben jij het 3D platform van de afdeling. Je kan de moeilijke en ongrijpbare kanten van de technologie subliem overdragen aan de 'domme' medicus; denk bijvoorbeeld aan een wetenschappelijke voordracht houden met nat haar en een zwemvest aan, waardoor de zaal in lachen uitbarstte en je er met de eerste prijs vandoor ging.

Ron, sinds het begin van de studententijd zijn we beste vrienden. De gezamenlijke weekendjes weg, vakanties en onvergetelijke momenten zijn ontelbaar geworden. Laten we zorgen dat we dat er in de toekomst in houden, aangezien we af en toe ook wel erg opgaan in het werk. Je bent altijd gepassioneerd en serieus geweest over je vak. Na je tijdelijke verblijf met Thomas in België voor zijn doctoraat, ben je nu zelf hard op weg naar diezelfde titel als parodontoloog/implantoloog. En als je patiënten uit Nederland voor jou naar België komen rijden, dan moet je wel perfecte zorg leveren. Ik weet zeker dat we over 40 jaar samen terugkijken op een mooie carrière en een nog veel mooiere vriendschap.

Beste co-auteurs, Ludo Beenen, Maarten Mourits, Hinke Marijke Jellema, Patricia Neomagus en Lidy Hartman, dank voor jullie hulp, feedback en aanvullingen. Zonder de afdelingen radiologie, oogheelkunde en orthoptie was dit proefschrift er niet geweest. Ook dank aan Nick Lobé voor de hulp met het scannen tijdens de kadaverstudies en Yvette Braaksma en collega's van de orthoptie voor alle orthoptische onderzoeken.

Beste stafleden, prof. dr. Smeele, prof. dr. Rozema, Jitske, Renée, Ronald, Jacco, Pim, Jean-Pierre en Tom, tijdens mijn opleiding tot MKA-chirurg probeer ik zoveel mogelijk te luisteren, mee te kijken en te vragen, om op die manier mijn kennis en handvaardigheid te verbeteren. Jullie zijn een breed



palet aan fantastische persoonlijkheden met verschillende uitmuntende eigenschappen. Ik ben trots dat ik onderdeel mag zijn van het team en dank jullie voor het geduld en de toewijding. Tom wil ik in het bijzonder bedanken. Vanaf het begin van de studietijd vrienden en mede door jouw enthousiasme en hulp ben ik bij de MKA-chirurgie terecht gekomen. Nog even en het 'van Riet MKA-robot leger' zal de wereld veroveren.

Beste mede-AIOS, Marie-Chris, Judith, Simone, Sophie, Willem, Johan, Karel, een hechte band met jullie tijdens de eerste echte stappen in de MKA-chirurgie is vanzelfsprekend. We zien elkaar immers meer dan het thuisfront, leren van elkaar en zorgen dat de afdeling zoveel mogelijk op rolletjes loopt. Marie-Chris, mijn eerste apexresectie heb ik onder jouw ontspannen begeleiding gedaan. Judith, vrolijk, passioneel en 'recht voor zijn/haar raap'. Simone, de rust zelve en alles onder controle. Sophie, niet de rust zelve, maar extreem sociaal en begaan met iedereen. Dank voor alle praktische hulp rondom het afronden van het proefschrift. Willem, structuur als basis (Excel/Evernote), gevoel voor didactiek, onuitputtelijk veel humor en een verbinder. Johan, nuchter (figuurlijk dan), altijd behulpzaam en meer tandheelkundige ervaring dan de meeste stafleden gok ik. Karel, net begonnen en nu al de onbetwiste dartskampioen van de afdeling.

Alle andere collega's van de afdeling MKA-chirurgie wil ik bedanken voor de samenwerking. Dank voor jullie geduld, hulp en de gezelligheid. Het eerste jaar van mijn opleiding is voorbijgevoegen. Een groot deel van de tijd was ik bezig met onderzoek, maar vanaf nu kan ik mij vol storten op de kliniek en koffie/lunchpauze!

Beste (oud-)bestuursleden van de VMTI, Jitske, Josje, Ingrid van Rijswijk, Ingrid Scheerboom, Kirsten, Fred, Steven, Joris, Erol, Dan, ik denk met veel plezier terug aan de vergaderingen, etentjes en de organisatie van alle congressen.

Lieve vrienden en vriendinnen, het dankwoord wordt een boek op zichzelf als ik jullie allemaal persoonlijk ga bedanken voor de steun de afgelopen jaren en wat jullie voor mij betekenen. Ik beloof dat ik, nu ik meer tijd heb, een mooi menu voor jullie persoonlijk zal samenstellen en koken en het jullie 'in persoon' zal vertellen.

Wel wil ik 'de jongens uit Goes' (Seb, Ruurd, Daan, Hidde, Yussel, Willem, Robbie) bedanken voor al meer dan twintig jaar vriendschap. Zonder jullie was het al meerdere keren geen 'Luctor et Emergo', maar 'ik worstel en verdrink'. Laten we nog vaak proosten op het leven!

His & Luuk, ik ken geen stel zo zorgzaam en attent als jullie. Ik ben blij dat we al zoveel jaren elkaar, ondanks drukke agenda's, blijven zien. De 020/010 strijdbijl kunnen we dan prima voor een avond begraven. Jullie zijn toppers.

Sip, van huisgenoten naar vrienden voor het leven. Je bent een uniek persoon en weet me altijd te verbazen. Hopelijk vergeef je me de frustratiemomenten (zoals opgefokte squashpotjes) als ik weer eens overwerkt was en er geen land met me te bezeilen was. Vanaf nu alleen maar 'smooth sailing', rustig vaarwater en de wind in de zeilen. Wanneer gaan we de boot afmaken?

Lieve schoonfamilie, Ad&Ellen, Jop&Gees, Jurre&Margje, dank voor de onaflatende interesse en steun tijdens het gehele studie/promotietraject. Het was nogal een rit. In Goes, Amsterdam en later in Bussum was/is er altijd tijd voor een goed glas wijn, Oosterschelde kreeft, Zeeuwse oesters en vooral lang natafelen. Carpe diem!

Lieve pa, Ton, alweer 15 jaar geleden, net voor ik ging studeren, ben je overleden, maar je staat wel aan de basis van alles wat ik tot nu toe heb bereikt. Bedankt daarvoor. Ook dank voor de goede en slechte eigenschappen die ik deels van je heb overgenomen: dezelfde humor, werklust, liefde voor koken/eten, maar soms ook een kort lontje als iets niet helemaal naar behoren gaat. Ik proost op je.

Lieve (half)zus, Anouk, Nouk, zonder jou had ik de stap naar Amsterdam nooit kunnen maken. Op zijn zachtst gezegd begon mijn studententijd wat onstuimig en soms lichtelijk destructief. Ik was af en toe niet de makkelijkste op de Postjeskade, maar toch trok je me weer uit de put. Je hebt me geleerd te genieten van Amsterdam, nieuwe mensen leren kennen, koken, eten en wijn. Samen staan we sterk.

Lieve moeder, Diny, ik ken niemand sterker en veerkrachtiger dan jij. Toen je een paar jaar geleden besloot naar Amsterdam te verhuizen, had je



binnen een half jaar meer van de stad gezien dan ik in de 10 jaar daarvoor. Zelfs met vrijwilligerswerk in het museum, golf, yoga, bioscoop/theater/ concertvoorstellingen en afspraken met vrienden, sta je toch altijd voor mij, Fem en Veer klaar als de agenda's weer eens voor problemen zorgen. Deze en alle voorgaande mijlpijlen had ik zonder jou zeker niet kunnen bereiken. De beste moeder en oma die er is.

Lieve Veerle, inmiddels alweer 2 jaar en wat vliegt de tijd sinds je geboren bent. Je bent heerlijk eigenwijs, lief, slim en soms juist wat verlegen de kat uit de boom aan het kijken. Daarnaast snel afgeleid en ongeduldig als iets niet lukt. Ik werk vaak veel en daarom schreeuw je de laatste tijd bij elk afscheid 'Papa niet werken!', maar ik weet zeker dat we in de toekomst samen nog veel liedjes gaan zingen, avonturen gaan beleven en gaan genieten van elkaar. Afgesproken?

Liefste, Fem, omdat we elkaar al zo lang kennen en al zo lang samen zijn, denk ik soms misschien dat wat we hebben gewoon is. We zijn dan misschien wel een beetje 'nuchtere import Zeeuwen', maar het is eigenlijk ongelooflijk speciaal! We zijn straks allebei medisch specialist, hebben een prachtige dochter, fantastische vrienden en genieten van het leven met lekker eten, wijn en leuke vakanties. Maar toch vinden we dat we te weinig hobby's hebben en niet genoeg sporten. Wat ben ik extreem trots op wat wij samen nu al bereikt hebben! Dank voor al je geduld de afgelopen jaren als ik weer zuchtend achter mijn laptop verscholen zat om te werken aan een onderzoek. Dank voor de prachtige cadeaus die je me altijd geeft. Dank dat je zo'n lieve en complete moeder voor Veerle bent. Ik weet dat je na mijn aanzoek vorig jaar in Italië graag snel het huwelijk had gepland, maar helaas laat dat door dit proefschrift en COVID-19 nog even op zich wachten. Wat in het vat zit verzuurt niet en ik beloof dat het een spetterende dag zal worden. Love you!



# About the author



The author of this PhD thesis was born on the 8th of June, 1987 in Utrecht, the Netherlands. He finished secondary school (bilingual athenaeum; International Baccalaureate English A2) in 2005 at 'Het Goese Lyceum' in Goes. He started studying Economics and Business Administration at the University of Amsterdam in the same year. In 2008, he decided to switch and study medicine at the Amsterdam Medical Center (AMC) in Amsterdam instead, as he wasn't stimulated enough by his previous study. The field of oral and maxillofacial (OMF) surgery sparked his interest quite soon. After finishing a scientific internship on predictive parameters of zygomatic bone fractures, he was invited to continue research as a PhD candidate in 2013 at the Department of OMF surgery at the AMC during his clinical rotations. He obtained his medical doctor degree in 2014 and started studying dentistry in 2015 at the Academic Centre for Dentistry Amsterdam (ACTA) to obtain his master's degree in 2019.

Between 2014 and 2019 he gained work experience in various areas. He worked for one year at the Department of OMF surgery at the AMC (ANIOS), as a teacher at the Department of Medical and Dental Interaction at ACTA, and as a medical doctor for Sanquin (donorarts). For four years he worked at the Department of OMF surgery at the Spaarne Gasthuis in Haarlem, under the inspiring supervision of professor A.G. Becking, to assist in the three-dimensional virtual planning of orthognathic patients. During these years, he developed profound interests in orthognathic surgery, maxillofacial trauma, and computer-assisted surgery. To improve his organisational and teaching skills, he was a faculty member of the SORG navigation course in 2017 and took part in the organisation of the BSSO IPS workshop in 2017. Over the years, he was a guest lecturer for dental hygiene students/postgraduates. He also had a board position at the Dutch society of medical and dental interaction (VMTI) for three years.

In September 2019, he started his residency in OMF surgery at the Amsterdam UMC location AMC (head: professor J. de Lange).

He currently lives in Amsterdam with Femke Alberts and their daughter Veerle (2018).







